

DOI: <https://doi.org/10.5554/22562087.e1020>

Erector Spinae Plane Block. A narrative review

*Bloqueo del plano del músculo erector de la espina.
Revisión narrativa de la literatura*

Carlos Eriel Largo-Pineda^{a,c} , Daniela González-Giraldo^{b,c} , Mario Zamudio-Burbano^{b,c} 

^a Anesthesiology, Universidad Militar Nueva Granada. Bogotá, Colombia.

^b Anesthesiology, Universidad de Antioquia. Medellín, Colombia.

^c IPS Universitaria Clínica León XIII. Medellín, Colombia.

Correspondence: Calle 69 No. 51c-24, Servicio de Anestesiología, IPS Universitaria Clínica León XIII. Medellín, Colombia.

Email: cegopimed@gmail.com

How to cite this article: Largo-Pineda CE, González-Giraldo D, Zamudio-Burbano M. Erector Spinae Plane Block. A narrative review. Colombian Journal of Anesthesiology. 2022;50:e1020

Abstract

The erector spinae plane (ESP) block is an interfascial block described in 2016 by Forero and collaborators, with wide clinical uses and benefits when it comes to analgesic control in different surgeries. This block consists of the application of local anesthetic (LA) in a deep plane over the transverse process, anterior to the erector spinae muscle in the anatomical site where dorsal and ventral branches of the spinal nerve roots are located.

This review will cover its clinical uses according to different surgical models, the existing evidence and complications described to date.

Keywords

Post-cardiac arrest syndrome; In-hospital cardiac arrest; Cardiopulmonary resuscitation; Return of spontaneous cardiac circulation; Ischemia-reperfusion injury.

Resumen

El bloqueo del plano del músculo erector de la espina (ESP, por sus siglas en inglés) es un bloqueo interfascial descrito en 2016 por Forero y colaboradores, con amplios usos clínicos y beneficios en relación con el control analgésico de diferentes modelos quirúrgicos. Este consiste en la aplicación de anestésico local (AL) en un plano profundo sobre apófisis transversa anterior al músculo erector de la espina, sitio anatómico donde se encuentra la bifurcación de los ramos dorsal y ventral de las raíces nerviosas espinales. En esta revisión, se expondrán los usos clínicos según diferentes modelos quirúrgicos, la evidencia que existe de ellos y las complicaciones descritas hasta la actualidad.

Palabras clave

Bloqueo nervioso; Anestesia y analgesia; Fascia; Anestesia regional; Anatomía regional.

INTRODUCTION

The erector spinae plane (ESP) block is a regional anesthesia technique first described by Forero et al. (1) as a modified interfascial block initially used for patients with chronic neuropathic thoracic pain to provide wide sensory blockade, including the anterior and posterior regions of the chest.

Reports and case series (2-6) have suggested good results, spurring interest in the scientific community and leading to studies designed to assess anatomic and physiologic considerations, as well as the clinical applications of this technique.

The usefulness and safety of the ESP block have been elucidated in different scenarios (1-3). As an analgesic/anesthetic technique, it appears to offer advantages over other regional options such as neuraxial and paravertebral blocks, which pose a higher risk of dural or pleural punctures and other side effects (3).

Although it needs to be highlighted that there are no learning curves for this block so far, it has positioned itself as an innovative technique described as easy to perform in the practice of anesthesia (1-8).

The purpose of this review is to summarize the main indications for the ESP block in the practice of anesthesia, and to document the complications described to this date. A broad literature search was conducted in PubMed, Google Scholar and the Cochrane Library between July 2018 and November 2020. The inclusion criteria were articles on ESP block identified in the search, including letters to the editor, case reports, case series, cadaveric studies, reviews, meta-analyses and clinical trials in both adult and pediatric populations. The exclusion criteria were articles in languages other than Spanish or English, animal studies or articles unrelated to the ESP block. The terms used were Erector Spinae Plane Block, ESP block, and Erector Spinae block.

The full texts of 80 articles were read and data on the surgical model, anatomic site pain, anesthetic dose and type, numerical pain scale, complications and

other relevant observations were collected. The most relevant findings are described in Tables 1 and 2.

ANATOMY

The thoracolumbar fascia (TLF) (9) is an important structure in the ESP block since it enables distal spread of the local anesthetic (LA) from the site of administration; it consists of fascia layers and aponeurotic tissue which separate paraspinal muscles from the posterior abdominal wall muscles; it extends cephalad, along the thoracic and cervical spine, up to the skull base, and caudal down to the sacroiliac level posteriorly (9-11).

The erector spinae muscles include the iliocostalis, longissimus and spinalis (multifidus); they arise from a common aponeurosis (the three columns of the broad tendon), form at the level of L5 and attach to the posterior inferior iliac crest, the posterior sacrum, the sacroiliac ligaments and the inferior sacral and lumbar spinous processes. Each muscle has its own cephalic insertion point: ribcage and C4-C6 vertebrae; thoracic and cervical transverse processes, mastoid and temporal bones; and upper lumbar and thoracic spinous processes, respectively (9-12).

The thoracic spinal nerves, known as intercostal nerves (T6 to T11) after they emerge from the intervertebral foramen, divide into posterior and anterior branches, innervating muscle structures, joints, pleura, peritoneum and skin of the dorsal and ventral regions of the thorax. Apart from their intercostal course, they have other divisions that traverse the abdomen to provide motor and sensory innervation to the anterior abdominal wall muscles (13).

The ESP block is classified as a block of the fascial plane of the erector spinae muscle. After it is administered, the local anesthetic spreads through the dorsal fascias described above. In the lumbar fascias and the lumbar interfascial triangle, it allows for anterior, posterior, cephalic

and caudal spread, involving the ventral and dorsal branches of the spinal nerves, as well as the communicating branches of the sympathetic chain which conduct presynaptic and postsynaptic fibers both in the thoracic as well as the lumbar spine, with the potential of providing visceral and somatic analgesia (1,8,9).

TECHNIQUE

The patient can be sitting or in lateral recumbency (1,14) with the side to be blocked facing superiorly. Several ways to orient the transducer in order to localize the target site have been described. Sagittal paramedian (14,15) and transverse placement (2) using a high-frequency linear probe have been proposed.

In the sagittal paramedian axis, the probe is placed at approximately 3 cm from the midline to localize the transverse process (T5 vertebra for thoracic interventions); it is suggested to begin lateral to medial, initially visualizing the ribs which appear markedly convex with a steeper angle (more rounded or U-shaped); when the transverse process is identified, 3 muscles come into view, namely, trapezius, rhomboid major and erector spinae (Figure 1). The rhomboid major is found only at the T5-T6 level (16). Having localized that view, an "in-plane" injection is performed (Figure 2).

The volume of LA varies in the literature. However, in cadaver models, a volume of 20 mL (1,17) to 30 mL (18) has been shown to extend from T2 to T9 when administered on the transverse process of T5 (2) (even from C5 to L3) (5,18), spanning a mean of 9 dermatomes (range 8-11) in the dorsal area, with 2.2 mL (1.81-2.5 mL) of LA per dermatome required (13); and from T2-T3 to T6-T9 in the anterolateral region, with variable extension to the axillary area and the medial aspect of the arm (19). In children, the use of a volume of 0.6 mL/kg has been reported (14).

TABLE 1. ESP block randomized clinical trials.

Surgical area	Author / Year	Study type	Pain	Surgical model/ intervention	Comparison	Sample	Level	Single dose vs. continuous	Laterality	Local anesthetic and dose	Mean NRS* afterwards	Conclusion	Complication	Primary outcome statistical value
Thorax	Barrios, 2020 (13)	CO	A	Rib fractures, herpes zoster neuritis, thoracostomy and myofascial pain syndrome		18	T5-T7	SD	U	0.5% B 20 mL	< 2	16 patients with pain modulation, mean blocked dermatome extension of 9 (range 8-11)	None	
	Ciftci, 2019 (28)	RCT	A	Videothoracoscopy	ESP vs. multi-modal analgesia	60	T5	SD	U	0.25% B 20 mL	ESP 1 vs. No ESP 5	ESP less POP pain and less rescue opioids. No adverse effects	None	Opioid use in ESP 10.00 ug ± 14.62 ug vs. no ESP 47.33 ug ± 16.17 ug, p < 0.001
	Gaballah, 2019 (29)	RCT	A	Videothoracoscopy	ESP vs. PVB	60	T5	SD	U	0.25% B 20 mL	ESP 1.13 vs. No ESP 5.13	ESP less POP pain, longer time to first rescue dose of analgesic, lower opioid use	None	POP in first 4 h lower in ESP group 1.87 ± 0.35 vs. 2.0 ± 0.01, p = 0.04, POP pain at 6 h lower in ESP group 3.33 ± 0.48 vs. 3.73 ± 0.45, p = 0.002. Time to first analgesia longer in ESP group 379.07 ± 7.78 vs. 296.04 ± 6.62 minutes, p < 0.001
	Chen, 2020 (30)	RCT	A	Videothoracoscopy	ESP vs. PVB vs. ICNB	75	T5	SD	U	0.375% R 20 mL	Three groups < 4	PPV less POP pain. Greater need for rescue analgesia in ESP. Higher morphine use at 24 h in ESP	Hematoma in 4 PVB patients, 5 ICNB, 0 ESP	Morphine use in PVB 10.5 (9-15) mg; ICNB 18 (13.5-22.1) mg; ESP 22 (15-25.1) mg; p = 0.000
Cardio	Nagaraja, 2018 (34)	RCT	A	Median sternotomy	Bilateral ESP vs. epidural catheter	50	T5	CC	BL	0.25% B 15 mL in each side and CC (0.125% B 0.1 mL/kg/h)	First 12 hours ESP 1.68 /10 vs. Epid 1.92/10 /// 24 hours ESP 1.44 /10 vs. Epid 2.08/10	ESP less POP at 24 hours, with no difference in NSR in first 12 hours, opioid use, spirometry, ICU length of stay. No adverse effects	None	NSR Epid 1.56 ± 1.08 vs. ESP 1.04 ± 0.98 P < 0.08 first 12 h // NRS Epid 2 ± 1.32 vs. ESP 0.8 ± 0.64 p < 0.0002 after 24 hours
	Borys, 2020 (36)	CO	A	Minimally invasive thoracotomy (mitral valve replacement)	ESP vs. IV analgesia	44	T4	SD	U	0.375% R 0.2 mL/kg	3.72 out of 10	Shorter mechanical ventilation time and shorter ICU stay	None	Oxycodone use in ESP group was 18.26 (95% CI: 15.55-20.98) mg
	Krishna, 2019 (37)	RCT	A	Median sternotomy	Bilateral ESP vs. tramadol + paracetamol	106	T6	SD	BL	R 0.375 % 3 mg/kg (1.5 mg/kg each side, 20-25 mL in each side)	< 4 out of 10 first 8 hours	More prolonged pain modulation in ESP group	None	NRS < 4/10 postextubation p = 0.0001 in favor of ESP

Surgical area	Author / Year	Study type	Pain	Surgical model/ intervention	Comparison	Sample	Level	Single dose vs. continuous	Laterality	Local anesthetic and dose	Mean NRS ^a afterwards	Conclusion	Complication	Primary outcome statistical value
Columna	Yayik, 2020 (40)	RCT	A	Lumbar spine decompression	ESP vs. control (PCA tramadol)	60	L3	SD	BL	0.25% B 20 mL in each side	ESP group < 2.4 at rest and < 2.6 dynamic in the first 24 hours	ESP less dynamic and static pain, less tramadol use	None	Higher tramadol use for control group (370.33 ± 73.27 mg and 268.33 ± 71.44 mg, p < 0.001). Static pain ESP 1.93 ± 0.87 vs. 3.83 ± 1.18 and dynamic pain 2.30 ± 0.60 vs. 4.63 ± 1.10 p < 0.001
	Singh, 2020 (41)	RCT	A	Major lumbar spine surgery	ESP vs. control	40	T10	SD	BL	0.5% B 20 mL in each side	ESP group < 3 vs. control group < 4	ESP less morphine use and lower pain scores than control group	None	Lower morphine consumption (1.4 ± 1.5 vs. 7.2 ± 2.0 mg p < 0.001) ESP
	Qiu, 2020 (42)	M	A	Lumbar spine surgery		171	T8 - L4	SD + C	BL	B, R, L		Effectiveness and safety of ESP for lumbar spine surgery still controversial		
Mama	Aksu, 2019 (43)	RCT	A	Breast surgery	ESP + PCA vs. control (PCA)	50	T2 and T4	SD	U	0.25% B 20 mL (10 mL for T2 and 10 mL for T4)	Both groups < 2	Morphine use significantly lower in ESP group at 6, 12 and 24 hours POP	None	Morphine use at 24 h lower in ESP 3.02 ± 2.06 mg vs. 13.2 ± 4.98 mg in control group, p < 0.001
	Swisher, 2020 (44)	RCT	A	Breast surgery without uni or bilateral mastectomy	ESP vs. PVB	100	T3 or T4	SD	U o BL	0.5% R CE 20 mL unilateral or 16 mL/ side for bilateral	ESP group 3 vs. PVB group 0	Higher pain scores and opioid use in ESP group. Lower POP morphine use for PVB group	None	Pain scores -3.0 a 0 (p = 0.0011)
	Gürkan, 2020 (45)	RCT	A	Breast cancer surgery	ESP vs. PVB vs. control (opioid only)	75	T4	SD	U	0.25% B 20 mL vs. 20 mL vs. opioid analgesia	ESP and PVB groups < 2 first 12 h < 5 first 24 h	Opioid use (no difference in ESP and PVB). VAS 1 and 6 hours POP (better in PVB than control, but no difference between ESP and control)	None	Morphine use at 24 hours 5.6 ± 3.43 mg in ESP group, 5.64 ± 4.15 mg PVB group and 14.92 ± 7.44 mg in control group, p = 0.001
	Gürkan, 2018 (46)	RCT	A	Breast cancer surgery	ESP vs. control (opioid only)	50	T4	SD	U	0.25% B 20 mL	< 2 in first 24 h for both groups	Pain modulation no different than control, 65% lower morphine use than in control group	None	Morphine use at 1, 6, 12, 24 hours lower in ESP 5.76 ± 3.8 mg vs. 16.6 ± 6.92 mg in control group, p < 0.05
	Leong, 2020 (47)	RS M	A	Breast surgery	ESP vs. no block vs. other blocks	861	T4	SD	U	0.25% B 20 mL	EPS group lower pain scores vs. no block group. ESP group higher pain scores vs. PNB group in first 12 hours	ESP less pain at 2, 6, 12, 24 h POP. Lower need for morphine and better recovery quality	Pneumo-thorax 2.6% PVB, 0% ESP	POP pain at 2 hours (-2.97 to -0.29, p = 0.02), at 6 hours (-1.49 to -0.30 p = 0.003), at 12 hours (-0.67 to -0.25 p < 0.0001), and at 24 h (-0.70 to -0.30 p < 0.00001). Lower morphine requirements for ESP group (-32.57 to -10.52) p = 0.00

Surgical area	Author / Year	Study type	Pain	Surgical model/ intervention	Comparison	Sample	Level	Single dose vs. continuous	Laterality	Local anesthetic and dose	Mean NRS ^a afterwards	Conclusion	Complication	Primary outcome statistical value
Mama	Altıparmak, 2019 (48)	RCT	A	Breast cancer surgery (radical mastectomy)	ESP vs. PEC2	38	T4	SD	U	0.25% B ESP 20 mL vs. PEC2 (20 mL between pectoralis minor and serratus + 10 mL between pectoralis major and pectoralis minor)	Similar pain scores (<1.5) between both groups at 15 and 30 minutes. Lower scores in PECS group after 60 min	Pain modulation greater in PEC2 group, lower tramadol use in PEC2 group		POP tramadol use lower in PEC2 group (132.78 ± 22.44) than in ESP group (196 ± 27.03) p=0.001
	Gad, 2019 (49)	RCT	A	Radical mastectomy	ESP vs. PEC2	50	T4	SD	U	0.25% L 20 mL	Scores below 20/100 in both groups	Lower opioid use in PECS, better pain modulation and lower POP morphine use	None	Opioid use higher in ESP group (16.7 ± 7.21) vs. (10.7 ± 3.12) p = 0.001
	Sinha, 2019 (50)	RCT	A	Modified radical mastectomy	ESP vs. PEC2	64	T4	SD	U	0.2% R 20 mL	PECS2 group 2 vs. ESP group 2.6	POP morphine use lower in PEC2 group		Morphine use lower in PEC2 (4.40 ± 0.94 mg) vs. ESP group (6.59 ± 1.35 mg; p = 0.000)
	El Gharmry, 2019 (51)	RCT	A	Radical mastectomy	ESP vs. PVB	70	T5	SD	U	0.25% B 20 mL	ESP group < 3 first 6 h, PVB group < 4 first 6 h	POP morphine use during first 24 hours and time to first analgesia requirement similar between both groups. No difference in the VAS, PONV or intraoperative fentanyl use between the two groups. POP morphine use during 24 hours was similar	4 patients in the PVB group developed pneumothorax, 0 in the ESP group	POP morphine use in ESP group (26.7 ± 2.1) vs. (27.3 ± 2.9) (p = 0.32)
	Moustafa, 2020 (52)	RCT	A	Radical mastectomy	ESP vs. PVB	102	T4	SD	U	0.25% B 20 mL	Not assessed	100% success rate in ESP vs. 77.8% in PVB. POP morphine use similar between both groups	None	100% success rate in ESP vs. 77.8% in PVB (χ ² =9.11 p = 0.002)
	Sharma, 2020 (53)	RCT	A	Breast cancer surgery (radical mastectomy + axillary lymph node resection)	ESP vs. control (opioid only)	60	T5	SD	U	0.5% R 0.4 mL/kg	ESP group < 1, control group < 4	Pain modulation similar in both groups, lower morphine use in ESP 43%	None	Morphine use in first 24 hours lower in ESP mean differences 2.1 (2.0–2.2), p 0.01
	Singh, 2019 (54)	RCT	A	Modified radical mastectomy	ESP vs. control (opioid only)	40	T5	SD	U	0.5% B 20 mL	ESP group 2.7 vs control group 4.2	Pain modulation higher and opioid use lower in ESP group	None	Morphine use in ESP (1.95 ± 2.01 mg) vs. control group (9.3 ± 2.36 mg) p = 0.01

Surgical area	Author / Year	Study type	Pain	Surgical model/ intervention	Comparison	Sample	Level	Single dose vs. continuous	Laterality	Local anesthetic and dose	Mean NRS* afterwards	Conclusion	Complication	Primary outcome statistical value
Mama	Yao, 2020 (55)	RCT	A	Radical mastectomy	ESP vs. placebo (0.9% NSS)	82	T4	SD	U	0.5% R 25 mL	ESP group with better overall scores on the QoR-15 24 hours POP, less static and dynamic pain	ESP group better recovery quality and pain modulation	None	Better recovery quality (95% CI: 9 to 12, $p < 0.001$)
	Altıparmak, 2019 (56)	RCT	A	Unilateral modified radical mastectomy	ESP with 0.375% B vs. ESP with 0.25% B	42	T4	SD	U	0.375% B vs. 0.25% 20 mL	ESP group with 0.375% B less than 2 vs. ESP group with 0.25% B less than 3.5 in first 12 h	POP tramadol use lower in ESP group with 0.375% B	None	POP tramadol use in ESP with 0.375% B (149.52 ± 25.39 mg) vs. ESP group with 0.25% B (199.52 ± 32.78 mg) ($p = 0.001$)
	Oksuz, 2019 (57)	RCT	A	Reduction mam-moplasty	ESP vs. tumescent anesthesia	44	T4	SD	BL	0.25% B 40 mL (20 mL in each side)	ESP group 4.1 ± 1.4 , control group 5.6 ± 1.0	Pain modulation, opioid use and patient satisfaction better in ESP group	None	Tramadol use 24 hours lower in ESP than tumescent, $p < 0.001$
Abdo-men	Altıparmak, 2019 (59)	RCT	A	Laparoscopic cholecystectomy	ESP vs. OSTAP	68	T7	SD	BL	0.375% B 20 mL each side in both groups	ESP group 1.5 vs. OSTAP group 2.2	Pain modulation and tramadol requirement lower in ESP group	None	Tramadol use lower in ESP (-72.40 to -48.19 $p < 0.001$)
	Tulgar, 2019 (60)	RCT	A	Laparoscopic cholecystectomy	ESP vs. OSTAP vs. control group (no block)	60	T9	SD	BL	0.5% B 20 mL, L2 10 mL 0.9% NSS 10 mL, 20 mL applied in each side in the block groups	ESP group 1.4 vs. OSTAP group 1.7 vs. control group 2.4	Pain modulation, need for tramadol and paracetamol analgesia lower in both block groups than in control group	None	NRS in ESP group 1 ± 1.10 , OSTAP 1.27 ± 1.41 , and control group 2.95 ± 1.81 , $p < 0.001$
	Tulgar, 2018, (61)	RCT	A	Laparoscopic cholecystectomy	ESP vs. control (opioid only)	30	T9	SD	BL	0.375% B 20 mL (0.375% in each side)	ESP group 1.4 vs. OSTAP group 2.3	Pain modulation, need for tramadol and paracetamol analgesia lower in ESP than in control group	None	NRS at 0-3 h ESP group 1.00 ± 1.13 vs. control group 2.88 ± 1.79 , $p < 0.01$
	Kwon, 2020 (62)	RCT	A	Laparoscopic cholecystectomy	ESP + RSB vs. RSB	53	T7	SD	BL	0.20% R 20 mL in each side	ESP group + RSB 2 vs. RSB 3	Lower opioid use, pain scores and remifentanyl use in ESP group + RSB	None	Use of analgesic at 6 h POP $41.9 \mu\text{g}$ ($165.1 \pm 67.7 \mu\text{g}$) in ESP group + RSB vs. $207 \pm 45.5 \mu\text{g}$ in RSB, $p = 0.012$, at 24 h POP $77.2 \mu\text{g}$ ($206.5 \pm 82.8 \mu\text{g}$) in ESP group + RSB vs. $283.7 \pm 102.4 \mu\text{g}$ in RSB $p = 0.004$

A: acute; B: bupivacaine; BL: bilateral; C: continuous; CC: continuous catheter; CI: Confidence interval; CO: cohort; Epid: Epidural; ICNB: intercostal nerve block; ICU: Intensive care unit; IV: intravenous; L: lidocaine; M: meta-analysis; NRS: numerical rating scale; OSTAP: oblique subcostal transverse abdominis plane; PCA: patient-controlled analgesia; PECS: pectoralis plane block; PEC2: pectoralis 2 block; PONV: postoperative nausea and vomiting; POP: postoperative; PVB: paravertebral block; QoR-15: quality of recovery; R: ropivacaine; RCT: randomized clinical trial; RSB: rectus sheath block; SD: single dose; SPB: serratus plane block; SR: systematic review; U: unilateral; VAS: visual analog scale; 0.9% NSS: 0.9% saline solution.

SOURCE: Authors.

TABLE 2. ESP block case series and reports.

Comprised anatomical site	Author/Year	Pain	Surgical model/Intervention	Sample	Level	SD vs. CC	Laterality	Dose and anesthetic
Thorax	Forero, 2016 (1)	A/C	Oncologic pain/costal fractures/VATS	4	T5	SD + C	U	0.25% B 20 mL/0.5% R 20 mL/1:1 L 2% + 0.5% R 20 mL/0.5% R 20 mL
	Muñoz, 2017 (3)	A	Thoracotomy for costal tumor resection (T11)	3	T8	SD	U	0.5% B with epinephrine 5 µg/mL 14 mL
	Adhikary, 2018 (5)	A	VATS	1	T5	SD + C	U	0.5% R 20 mL + 0.2% R infusion 8 mL/h
	De la Cuadra, 2018 (14)	A	Thoracotomy for correction of diaphragmatic paresis	1	T9	C	U	LB 8 mL initial bolus, 0.1% infusion 3 mL/h
	Forero, 2017 (16)	A	Thoracotomy for lobectomy	1	T5	C	U	0.5% R 25 mL + infusion 8 mL/h 0.2% R
	Wilson, 2018 (25)	A	VATS (metastasis for T11 paraspinal thymoma)	1	T5	SD	U	0.5% R 30 mL
	Hu, 2019 (26)	A	VATS (bullectomy)	1	T5	SD	U	0.375% R 20 mL
	Navarro, 2018 (27)	A	VATS (lung metastases/cystic carcinoma/lobectomy)	4	T5	C	U	0.5% B 20 mL + continuous infusion of 0.15% R 12 mL/h (first and second patients), 0.15% R at 7-12 mL/h (third patient) and 0.15% R at 12 mL/h (fourth patient)
	Raft, 2019 (32)	A	Thoracotomy	1	T5	SD + C	U	0.5% R 20 mL + 0.2% R infusion 8 mL/h
	Kelava, 2018 (33)	A	Thoracotomy for lung transplant	1	T5	C	U	0.25% B 15 mL + 0.2% R infusion 10 mL/h, 10 mL boluses every 4 hours while the patient remained intubated and, following extubation, 8 mL/h infusions with boluses of 12 cm ³
	Leyva, 2020 (35)	A	Minimally invasive thoracotomy (mitral valve replacement)	1	T7	C	U	0.125% bupivacaine at 7 mL/h
	Gaio, 2018 (65)	A	Thoracotomy for paracardiac teratoma resection	1	T5	C	U	0.2% R 5 mL (0.45 mL/kg) plus continuous infusion of 0.1% R at 2 mL/hour
	Nardiello, 2018 (66)	A	Sternal reconstruction (pectum excavatum/pectum carinatum)	2	T5	SD	BL	0.25% B 20 mL on each side
	Forero, 2017 (22)	C	Post-thoracotomy chronic pain	7	T5-T6	SD	U	R. Doses varied between 0.25 and 0.50%, and 20-30 mL volume
	Hamilton, 2017 (17)	A	Costal fractures	1	T5	C	U	0.125% B 10 mL/h
	Ahiskalioglu, 2020 (23)	C	Chronic thoracic oncologic pain	1	T5	C	U	0.25% B 20 mL plus 0.250% B infusion 8 mL/h and 5 mL/h boluses
	Ueshima, 2018 (21)	A	Acute pain management after postherpetic neuralgia	1	T6	SD	U	0.25% LB 10 mL
Breast	Bonvicini, 2017 (6)	A	Siliconoma excision + breast implant	1	T5	SD	U	R 75 mg + M 20 mg 25 mL
	Nair, 2018 (15)	A	Modified radical mastectomy + lymph node resection	5	T4	SD	U	0.25% B 30 mL
	Ueshima, 2018 (73)	A	Radical mastectomy	1	T4	SD	U	0.25% L 10 mL

Comprised anatomical site	Author/Year	Pain	Surgical model/Intervention	Sample	Level	SD vs. CC	Laterality	Dose and anesthetic
Spine	Ueshima, 2017 (38)	A	Thoracic vertebral surgery (lumbar stenosis and spinal cord tumor resection)	2	T5	SD	BL	0.375% L 40 mL (20 mL each side)
	Canturk, 2019 (39)	A	Spondylolisthesis correction	1	L1	SD	BL	0.25% B 10 mL, 1% P 10 mL
Abdomen and pelvis	Hannig, 2018 (7)	A	Laparoscopic cholecystectomy	3	T7	SD	BL	0.5% R 20 mL
	Chin, 2017 (2)	A	Laparoscopic bariatric surgery	3	T7	SD/SD/C	BL	1% R 5 mL + 2% L 5 mL + 0.9% NSS 10 mL / 0.5% R 20 mL / 0.5% R 20 mL
	Tulgar, 2018 (58)	A	Laparoscopic abdominal surgery	3	T8	SD	BL	0.5% B 10 cm3, 2% L 5 cm3, 0.9% NSS 5 cm3
	Restrepo, 2017 (64)	A	Major abdominal surgery (open radical cystoprostatectomy)	1	T8	C	BL	2% L 3 mL + 0.25% B 10 mL + continuous infusion of 0.1% B at 6 mL/h
	Aksu, 2019 (67)	A	Laparoscopic cholecystectomy	3	T7	SD	U	0.25% B at 0.5 mL/kg
	Hernández, 2018 (68)	A	Inguinal hernia repair (anesthetic)	1	T6	SD	U	0.4 mL/kg (1:1 solution of 0.25% B and 1% L)
	Chin, 2017 (18)	A	Ventral hernia repair	4	T7	SD	BL	0.5% R + adrenaline 5 µg/ mL 20 mL/ 0.5% R + dexamethasone 4 mg 30 mL / 0.5% R + dexamethasone 4 mg 20 mL/ R 0.5% + dexamethasone 4 mg 20 mL
	Selvi, 2018 (75)	A	Cesarean section	1	T11	SD	BL	0.5% B 15 mL + 2% L 5 mL + 0.9% NSS 5 mL
	Altinpulluk, 2018 (63)	A	Cesarean section	1	T9	SD	BL	0.25% B 20 mL
	Forero, 2017 (24)	C	Chronic shoulder pain	1	T2	SD	U	0.5% B 20 mL
Limbs	Tulgar, 2018 (69)	A	Hip arthroplasty	1	L4	SD	U	0.5% B 15 mL, 2% L 5 mL, 0.9% NSS 10 mL
	Bugada, 2018 (70)	A	Hip replacement/surgical revision of recurrent hip dislocation	2	L4	C	U	0.75% R 25 mL, PCA infusion 0.5 mL/h + 20 mL bolus every 3 h
	Darling, 2018 (71)	A	Surgical hip dislocation and femur osteotomy	1	T12	C	U	0.2% R 10 mL
	Balaban, 2019 (72)	A	Total knee arthroplasty	1	L4	C	U	0.375% B 30 mL
	Am J Emerg Med., 2019 (74)	C	Regional complex syndrome in right ankle and foot	1	L4	SD	U	0.5% B + 2% L 30 mL

A: acute; B: bupivacaine; BL: bilateral; C: chronic; CC: continuous catheter; L: lidocaine; LB: levobupivacaine; NSS: 0.9% saline solution; PCA: patient-controlled analgesia; R: ropivacaine; 0.9%; SD: single dose; U: unilateral; VATS: video-assisted thoracoscopic surgery.

SOURCE: Authors.

CLINICAL APPLICATIONS OF THE ERECTOR SPINAE BLOCK

The technique is apparently safe and easy to implement (4,8); however, there are no studies with large numbers of patients supporting its application in certain conditions. We describe its use in the setting

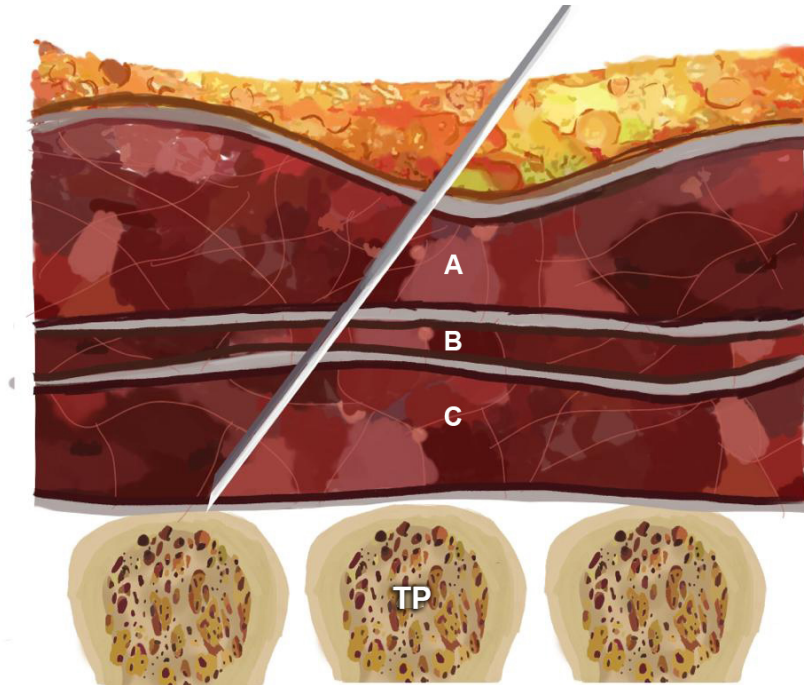
of chronic pain (1-4,18) and cardiac, thoracic, abdominal, breast and limb surgery, with evidence from randomized clinical trials (RCT) in some of these areas (20).

In the original report (1) and in other similar reports (21), the ESP block was performed in adult patients with chronic neuropathic pain (postherpetic neuralgia

and chronic neuropathic pain secondary to rib fractures). Later, Forero described a case series in post-thoracotomy chronic neuropathic pain (22), followed by new publications showing favorable results (23), including chronic shoulder pain (24).

In video-assisted thoracic surgery (VATS) for lobectomy, adequate pain

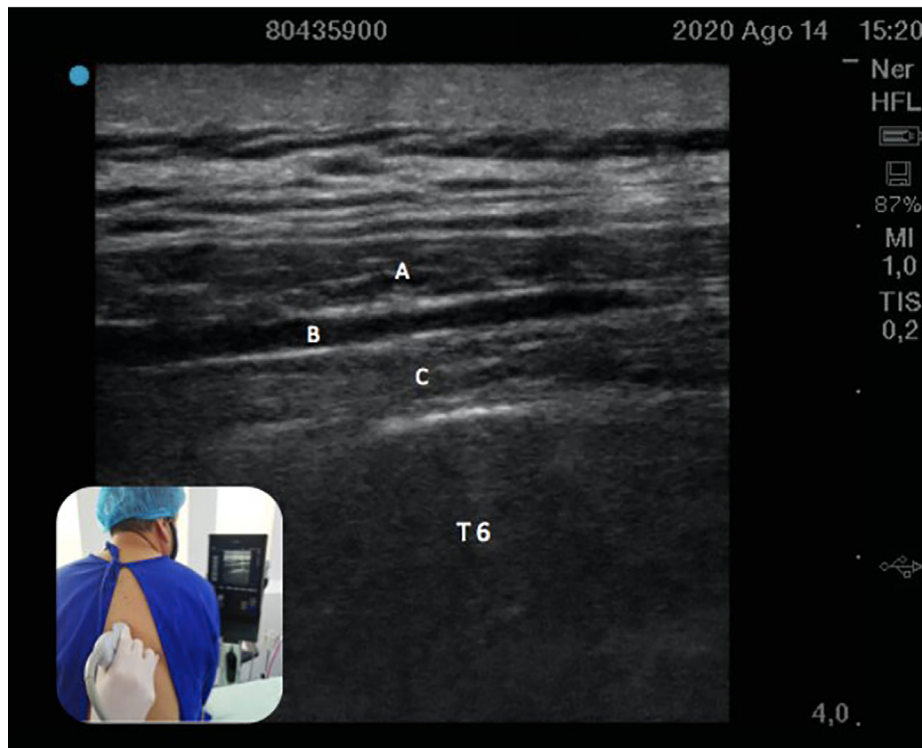FIGURE 1. Schematic representation of needle position for the ESP block.



A: trapezius; B: rhomboid major; C: erector spinae plane. TP: transverse process.

SOURCE: Authors.

FIGURE 2. Ultrasound technique and view of the transverse process and the three paraspinal muscles superficial to it, identified from superficial to deep.



A: trapezius; B: rhomboid major; C: Erector spinae at the level of the transverse process of T6.

SOURCE: Authors.

modulation has been documented (1). Reports have described the use of this block in cases where epidural analgesia or any other regional technique is more risky (25,26), is contraindicated or is more technically challenging (27). One RCT compared ultrasound-guided ESP block plus intravenous analgesia in 60 patients undergoing VATS. It was found that the use of opioids at 1, 2, 4, 8, 16 and 24 hours, and dynamic and static pain scores at those time points, were statistically lower in the ESP block group (5 patients out of 30) than in the control group (22 patients out of 30) (28). In the latter, the rates of nausea and pruritus were higher and there were no differences between the groups in terms of other adverse effects.

When the serratus plane and the ESP were compared for VATS in 60 adult patients, a significantly lower score for static pain as well as a lower dynamic pain score were found in the ESP group when compared to the serratus plane group 4-6 hours after the intervention. Similarly, the time to first analgesic requirement was longer in the ESP group, with no relevant side effects (29).

Despite its good results, when compared to the paravertebral block (PVB), the ESP block is not as favorable. An RCT published in 2020 (30) compared ESP vs. PVB vs. intercostal nerve block (ICNB) in 75 patients undergoing VATS and showed better postoperative pain (POP) control in the PVB group and a higher need for rescue analgesia in the ESP group, with no differences in the comparison between ESP and ICNB. However, pain scores were similar at different POP time points in the three groups.

Thoracotomy for lobectomy

The successful use of this technique as rescue has been reported in cases of failed thoracic peridural analgesia (16). According to some publications, the failure rate of the peridural neuraxial technique ranges between 11.2% (31) and 32% (32);

for this reason, the continuous ESP block is an option that offers excellent results in this group of patients. Likewise, the use of this block in two thoracic levels has been described (32), but RCTs showing superiority when compared with single-level injection are needed. Case reports have been described in POP analgesia after thoracotomy for lung transplant (33). In summary, in thoracic surgery, there is support for the use of the ESP block in VATS, thoracotomy for lobectomy, lung transplantation, and as rescue in cases of failed peridural analgesia.

Cardiac surgery

A prospective, randomized study assigned 50 patients to two groups: continuous epidural thoracic analgesia and continuous bilateral ESP block for the management of perioperative pain. Dynamic and static pain scores were similar in both groups at different time points during the first 12 hours; however, after 24 hours and up until 48 hours, pain was lower and statistically significant in the ESP block group when compared to epidural analgesia. There were no differences in ICU length of stay or the need for invasive mechanical ventilation (MV) (34). The ESP block used as part of multimodal analgesia in patients undergoing mitral and/or tricuspid valve repair through right minithoracotomy was analyzed in a case report (35) and also in a cohort study, which found that the time on MV as well as the ICU length of stay were shorter in the ESP block group (36).

An RCT published in 2019 compared bilateral ESP block vs. conventional analgesia in 106 patients undergoing cardiac surgery with by-pass circulation. In the ESP group, ultrasound-guided block at the level of T6 was performed before anesthetic induction. The results showed lower scores on the numerical pain scale (NPS) and longer analgesia duration in the bilateral ESP block group (37).

Spinal surgery

Current evidence is insufficient to support the generalized use of the ESP block; however, cases of its use have been described in spinal cord tumor resection surgery, laminoplasty for spinal canal stenosis (38) and correction of spondylolisthesis, with good results, opioid sparing and no complications (39). To this date, two RCTs (40,41) have been conducted, showing promising analgesic results in lumbar spine surgery, with no adverse effects. Notwithstanding the above, a systematic review carried out in 2020 concluded that the effectiveness and safety of this block for lumbar spine surgery are controversial (42).

Breast surgery

The ESP block has been gaining importance in breast surgery as a result of adequate analgesic response (6) and opioid sparing effect. RCTs comparing the ESP block with other techniques such as PVB (44) or intravenous techniques have been performed in recent years, showing superiority for fascial blocks when compared with intravenous strategies, as well as similar results in terms of pain control and opioid use (45,46).

In radical mastectomy, some RCTs comparing pectoralis nerve block (PECS) vs. ESP block have shown better POP results in the PECS group (47-50). Although no differences have been reported (51) when comparing the ESP and paravertebral blocks in terms of POP opioid use at 24 hours, pain scores, or PONV, shorter localization time by anesthetists with (44) or without (52) experience in regional techniques has been described in the case of the ESP block. Moreover, a comparison between the ESP block and intravenous analgesia (53) showed significantly lower POP morphine use and lower scores on the numerical pain scales in the first 4 hours in patients receiving the ESP block (54).

One RCT (55) compared the quality of POP recovery in patients taken to

modified radial mastectomy using LA vs. placebo, with better quality of recovery in the group assigned to the LA technique according to the QoR-15 questionnaire. A systematic review and meta-analysis (47) found that, in this surgical model, the ESP block offers superior analgesia and lower POP oral morphine use when compared to no use of regional techniques, as well as similar analgesic effects as those of the PVB, with absent risk of pneumothorax and other complications. The dose and useful anesthetic concentration are not clear yet; however, a recent RCT (56) compared two anesthetic concentrations in the ESP block, showing that 0.375% bupivacaine concentrations offer better analgesic results than 0.25% concentrations.

In other surgical models such as reduction mastectomy, a double-blind RCT (57) of 44 women comparing tumescent anesthesia vs. ESP block in terms of POP analgesia requirement, pain scores and patient satisfaction showed that the use of tramadol was significantly lower in the ESP block group as was also the case with pain scores at several time points during the first 24 hours and the need for additional analgesia, with improved patient satisfaction.

Considering that the erector spinae muscle extends towards the inferior spinal region, the ESP block at the level of T7-T8 allows the spread of the anesthetic mix to the inferior thoracoabdominal nerves that provide abdominal innervation. Moreover, the mechanism of action includes penetration of the LA into the paravertebral space, with action on the ventral and dorsal branches as well as the communicating branches containing sympathetic nerve fibers, thus providing sensory, somatic and visceral blockade in abdominal surgery (2). Against this backdrop, a report of 3 patients taken to laparoscopic bariatric surgery with adequate analgesic response to the ESP block has been described (2). Lower opioid requirements have been reported in case series (7,58) using this technique in patients undergoing laparoscopic ventral hernia repair (2) and in different laparoscopic surgery models.

Laparoscopic cholecystectomy

Three RCTs have been found: the first (59) with 76 patients, comparing the ESP block vs. transversus abdominis plane (TAP) block, showed that the POP use of tramadol and pain scores were significantly lower in the ESP group. The second study compared the same regional techniques in 72 patients in terms of the NRS score, paracetamol and tramadol consumption and the need for rescue analgesia (60) and it showed that pain intensity was similar between the two groups in the first 3 hours, while the consumption of additional analgesics was comparable. A third RCT (61) with 36 patients compared the ESP block vs. multimodal analgesia and showed that pain on the NRS was lower in the ESP block group during the first 3 hours, with no differences after that time; in turn, tramadol consumption and additional analgesic requirements were lower in the ESP group. These conclusions were also supported by a meta-analysis (62).

Lower abdominal surgery

In lower abdominal surgery, particularly in gynecological surgery for cesarean section, one case of bilateral ESP block for effective and lasting POP analgesia in a patient taken to an emergent procedure under general anesthesia (63) was found. Another case described a male patient taken to major abdominal surgery (open radical cystoprostatectomy) who received continuous analgesia with bilateral ESP block with very good analgesic results (64).

Pediatric patients

In these patients, the ESP block appears to be a safe and effective analgesic option, especially in thoracotomy (3,14,65). In other thoracic surgery models, the use of the ESP block has been described in pediatric patients undergoing pectum excavatum and pectum carinatum correction with

scores on the visual analog scale lower than 4 and absence of intraoperative and long-term postoperative opioid requirement (66). Likewise, case series (67) of pediatric patients described laparoscopic cholecystectomy with regional analgesia provided by the ESP block, showing adequate POP pain control and patient satisfaction. Also, a case report (68) described the use of a single-dose ESP block as anesthetic method for inguinal hernia repair in a two-month-old patient (born at 29 weeks of gestation) weighing 2.5 kg, with hemodynamic stability during the 35 minutes of the procedure, oral intake tolerance over the following 6 hours and a pain score of 0 on the FLACC (Face, Legs, Activity, Cry, Consolability) scale over the next 24 hours.

Lower extremities

Finally, in surgery involving the lower limbs, some published case reports show potential analgesic effectiveness of the ESP block, considering LA spread to the lumbar plexus, in surgical models such as hip arthroplasty (69) and knee arthroplasty (72); however, studies of better methodological quality are needed in order to arrive at a conclusion regarding the role of the ESP block in these procedures.

COMPLICATIONS

The ESP block appears to avoid the types of complications that can arise with the use of other regional techniques, including hypotension, permanent spinal cord injury and urinary retention with epidural analgesia, epidural spread, vascular puncture in PVB, and pneumothorax in intercostal nerve blocks and PVB (8,47). However, cases of pneumothorax (73) and priapism (74) have been reported in two patients subjected to the ESP block.

One case of motor blockade was recently described as an unexpected side effect of the ESP block in a patient undergoing cesarean section who refused neuraxial techniques (75). During her stay

in the postanesthetic care unit (PACU), bilateral motor weakness and sensory deficit between the T9 and L3 dermatomes were documented. Motor strength began to return after 13 hours, with complete resolution at 16 hours. The authors of this case propose LA infiltration into the lumbar plexus as the first explanation, or spread through the epidural space, considering that, on neurological examination, the patient showed weakness of the psoas, iliac and quadriceps muscles, confirming compromise of the spinal nerves at L1, L2 and L3, and of the femoral nerve.

The absence of important blood vessels and neural structures in immediate proximity minimizes concerns regarding the development of clinically significant hematomas. However, until more clinical data are available, caution is recommended in patients with coagulation disorders or who are receiving perioperative anticoagulation (76).

Although complications have been described generally with the in-plane ultrasound-guided approach, the use of the ESP with the out-of-plane approach using the convex transducer for hip (69), shoulder, thoracic, breast and abdominal surgery has shown a similar rate of efficacy and complications (77).

CONCLUSION

The ESP block is presented as an effective analgesic management option in anesthesia and should be considered as part of the multimodal analgesia strategies on the basis of its good analgesic results, low incidence of complications and less side effects when compared with epidural analgesia, and its wide applications in different surgical models. Therefore it may be considered as a safe, simple and optimal analgesic alternative (1,3,8).

Larger studies and more in-depth research are required in order to gain more insight into the mechanism of action, side effects and duration of the effects of this intervention.

ACKNOWLEDGEMENTS

Authors' contributions

LPCE: Conception of the original project, planning of the study, interpretation of the results, drafting and approval of the final manuscript.

GGD and ZBM: Planning of the study, interpretation of the results, drafting and approval of the final manuscript.

Assistance for the study

None declared.

Financial support

None declared.

Conflict of interest

None declared.

Presentations

None declared.

Appreciation

To our families, for their unconditional support.

REFERENCES

- Forero M, Adhikary SD, López H, Tsui C, Chin KJ. The erector spinae plane block a novel analgesic technique in thoracic neuropathic pain. *Reg Anesth Pain Med*. 2016;41(5):621-7. doi: <http://www.doi.org/10.1097/AAP.0000000000000451>
- Chin KJ, Malhas L, Perlas A. The erector spinae plane block provides visceral abdominal analgesia in bariatric surgery a report of 3 cases. *Reg Anesth Pain Med*. 2017;42(3):372-6. doi: <http://www.doi.org/10.1097/AAP.0000000000000581>
- Muñoz F, Cubillos J, Bonilla A, Chin KJ. Erector spinae plane block for postoperative analgesia in pediatric oncological thoracic surgery. *Can J Anesth/J Can Anesth*. 2017;10-2. doi: <http://www.doi.org/10.1007/s12630-017-0894-0>
- Chin KJ, Adhikary S, Forero M. Is the erector spinae plane (ESP) block a sheath block? A reply 'Medicolegal' or 'patient-centred' consent? *Anaesthesia*. 2017;72:910-24. doi: <http://www.doi.org/10.1111/anae.13926>
- Adhikary S Das, Pruett A, Forero M, Thiruvankatarajan V. Erector spinae plane block as an alternative to epidural analgesia for post operative analgesia following video assisted thoroscopic surgery : A case study and a literature review on the spread of local anaesthetic in the erector spinae plane. *Indian J Anaesth*. 2018;62(1):83-6. doi: http://www.doi.org/10.4103/ija.IJA_693_17
- Bonvicini D, Giacomazzi A, Pizzirani E. Use of the ultrasound-guided erector spinae plane block in breast surgery Use of the ultrasound-guided erector spinae plane block in breast surgery. *Minerva anestesiol*. 2017;2018;83(10):1111-2. doi: <http://www.doi.org/10.23736/S0375-9393.17.12015-8>
- Hannig KE, Jessen C, Soni UK, Børglum J, Bendtsen TF. Case report erector spinae plane block for elective laparoscopic cholecystectomy in the ambulatory surgical setting. *Case Rep Anesthesiol*. 2018;2018:1-6. doi: <https://doi.org/10.1155/2018/5492527>
- El-Boghdady K, Pawa A. The erector spinae plane block: plane and simple. *Anaesthesia*. 2017;72:427-38. doi: <http://www.doi.org/10.1111/anae.13830>
- Willard FH, Vleeming A, Schuenke MD, Danneels L, Schleip R. The thoracolumbar fascia: anatomy, function and clinical considerations. *J Anat*. 2012;507-36. doi: <http://www.doi.org/10.1111/j.1469-7580.2012.01511.x>
- Benjamin M. The fascia of the limbs and back – a review. *J Anat*. 2009;(214):1-18. doi: <http://www.doi.org/10.1111/j.1469-7580.2008.01011.x>
- Vleeming A, Pool-Goudzwaard A, Stoeckart R, van Wingerden J-P, Snijders CJ. The posterior layer of the thoracolumbar fascia. *Spine (Phila Pa 1976)*. 1995;20(7):753-8.
- Stecco A, Macchi V, Porzionato A, Masiero S, Tiengo C, Delmas V, et al. Pectoral and femoral fasciae: common aspects and regional specializations. *Surg Radiol Anat*. 2009;31:35-42. doi: <http://www.doi.org/10.1007/s00276-008-0395-5>
- Barrios A, Camelo J, Gómez J, Forero M, Peng PWH, Visbal K, et al. Evaluation of sensory mapping of erector spinae plane block. *Pain Physician*. 2020;23(5):289-95.
- De la Cuadra-Fontaine JC, Concha M, Vuletin F, Arancibia H. Continuous erector spinae plane block for thoracic surgery in a pediatric patient. *Pediatr Anesth*. 2018;28:74-5. doi: <http://www.doi.org/10.1111/pan.13277>
- Nair AS, Seelam S, Naik V, Rayani BK. Opioid free mastectomy in combination with ultrasound guided erector spinae block : A series of five cases. *Indian J Anaesth*. 2018;62(8):632-4. doi: http://www.doi.org/10.4103/ija.IJA_314_18
- Forero M, Rajarathinam M, Adhikary S, Chin KJ. Continuous erector spinae plane block for rescue analgesia in thoracotomy after epidural failure: a case report. *A Case Reports*. 2017;8(10):254-6. doi: <http://www.doi.org/10.1213/XAA.0000000000000478>
- Hamilton DL, Manickam B. Erector spinae plane block for pain relief in rib fractures. *Br J Anaesth*. 2016;118(3):474-5. doi: <http://www.doi.org/10.1093/bja/aex013>
- Chin KJ, Adhikary S, Sarwani N, Forero M. The analgesic efficacy of pre-operative bilateral erector spinae plane (ESP) blocks in patients having ventral hernia repair. *Anaesthesia*. 2017;72:452-60. doi: <http://www.doi.org/10.1111/anae.13814>
- Wild K, Chin KJ. Regional techniques for thoracic wall surgery. *Curr Anesthesiol Rep*. 2017;7(2):212-9. doi: <http://www.doi.org/10.1007/s40140-017-0212-y>
- Layera S, Bravo D, Aliste J. Bloqueos de tronco. *Rev Chil Anest*. 2020;49:65-78. doi: <http://www.doi.org/10.25237/revchil anestv49n01.06>
- Ueshima H, Otake H. Erector spinae plane block for pain management of wide post-herpetic neuralgia. *J Clin Anesth*. 2018;51:37. doi: <https://doi.org/10.1016/j.jclinane.2018.07.010>

22. Forero M, Rajarathinam M, Adhikary S, Chin KJ. Erector spinae plane (ESP) block in the management of post thoracotomy pain syndrome: A case series. *Scand J Pain*. 2017;2-6. doi: <http://dx.doi.org/10.1016/j.sjpain.2017.08.013>
23. Ahiskalioglu A, Alici HA, Ciftci B, Celik M, Karaca O. Continuous ultrasound guided erector spinae plane block for the management of chronic pain. *Anaesth Crit Care Pain Med*. 2020;38(4):395-6. doi: <http://dx.doi.org/10.1016/j.accpm.2017.11.014>
24. Forero M, Rajarathinam M, Adhikary S, Das, Chin KJ. Erector spinae plane block for the management of chronic shoulder pain: a case report. *Can J Anesth/J Can Anesth*. 2018;65(3):288-93. doi: <http://www.doi.org/10.1007/s12630-017-1010-1>
25. Wilson J, Lohser J, Klaibert B. Erector spinae plane block for postoperative rescue analgesia in thoracoscopic surgery to the editor. *J Cardiothorac Vasc Anesth*. 2018;32:5-7. doi: <https://doi.org/10.1053/j.jvca.2018.06.026>
26. Hu B, Zhou H, Zou X. The erector spinae plane block (ESPB) for non-intubated video-assisted thoracoscopic surgery. *J Clin Anesth*. 2019;54:50-1. doi: <https://doi.org/10.1016/j.jclinane.2018.10.032>
27. Luis Navarro JC, Seda Guzmán M, Luis Moreno C, López Romero JL. The erector spinae plane block in 4 cases of video-assisted thoracic surgery. *Rev Esp Anestesiol Reanim*. 2020;65(4):204-8. doi: <https://doi.org/10.1016/j.redar.2017.12.004>
28. Ciftci B, Ekinici M, Celik EC, Tukac IC, Bayrak Y, Atalay YO. Efficacy of an ultrasound-guided erector spinae plane block for postoperative analgesia management after video-assisted thoracic surgery: a prospective randomized study. *J Cardiothorac Vasc Anesth*. 2020;34:444-9. doi: <https://doi.org/10.1053/j.jvca.2019.04.026>
29. Gaballah KM, Soltan WA, Bahgat NM. Ultrasound-guided serratus plane block versus erector spinae block for postoperative analgesia after video-assisted thoracoscopy: a pilot randomized controlled trial. *J Cardiothorac Vasc Anesth*. 2020;33(2019):1946-53. doi: <https://doi.org/10.1053/j.jvca.2019.02.028>
30. Chen N, Qiao Q, Chen R, Xu Q, Zhang Y, Tian Y. The effect of ultrasound-guided intercostal nerve block, single-injection erector spinae plane block and multiple-injection paravertebral block on postoperative analgesia in thoracoscopic surgery: A randomized, double-blinded, clinical trial. *J Clin Anesth*. 2020;59:106-11. doi: <https://doi.org/10.1016/j.jclinane.2019.07.002>
31. Jhy Y, Gates S, Bv N, Mja W, F GS, Jhy Y, et al. Paravertebral block versus thoracic epidural for patients undergoing thoracotomy (Review). *Cochrane Database Syst Rev*. 2016;(2). doi: <http://www.doi.org/10.1002/14651858.CD009121.pub2>
32. Raft J, Chin KJ, Belanger M, Clairoux A, Ri-chebé P, Brulotte V. Continuous erector spinae plane block for thoracotomy analgesia after epidural failure. *J Clin Anesth*. 2019;54(September 2018):132-3. doi: <https://doi.org/10.1016/j.jclinane.2018.10.024>
33. Kelava M, Anthony D, Elsharkawy H. Continuous erector spinae block for postoperative analgesia after thoracotomy in a lung transplant recipient. *J Cardiothorac Vasc Anesth*. 2020;32(2018):2018-20. doi: <https://doi.org/10.1053/j.jvca.2018.04.041>
34. Nagaraja PS, Ragavendran S, Singh NG, Asai O, Bhavya G, Manjunath N, et al. Comparison of continuous thoracic epidural analgesia with bilateral erector spinae plane block for perioperative pain management in cardiac surgery. *Ann Card Anaesth*. 2018;21(3):323-7. doi: http://www.doi.org/10.4103/aca.ACA_16_18
35. Muñoz Leyva FM, Mendiola WE, Bonilla AJ, Cubillos J, Moreno DA, Chin KJ. Continuous Erector Spinae Plane (ESP) Block for Postoperative Analgesia after Minimally Invasive Mitral Valve Surgery. *J Cardiothorac Vasc Anesth*. 2020;32(2018):2271-4. doi: <https://doi.org/10.1053/j.jvca.2017.12.020>
36. Borys M, Gawęda B, Horeczy B, Kolowca M, Olszówka P, Czuczwar M. Erector spinae-plane block as an analgesic alternative in patients undergoing mitral and / or tricuspid valve repair through a right mini-thoracotomy – an observational cohort study. *Videosurgery Other Miniinvasive Tech*. 2020;1(March):208-14. doi: <https://doi.org/10.5114/wiitm.2019.85396>
37. Krishna SN, Chauhan S, Bhoi D, Kaushal B, Hasija S, Sangdip T, et al. Bilateral erector spinae plane block for acute post-surgical pain in adult cardiac surgical patients: a randomized controlled trial. *J Cardiothorac Vasc Anesth*. 2020;33(2019):368-75. doi: <https://doi.org/10.1053/j.jvca.2018.05.050>
38. Ueshima H, Otake H. Clinical experiences of ultrasound-guided erector spinae plane block for thoracic vertebra surgery. *J Clin Anesth*. 2017;38(August 2016):137. doi: <http://dx.doi.org/10.1016/j.jclinane.2016.12.028>
39. Canturk M. Ultrasound-guided bilateral lumbar erector spinae plane block for postoperative analgesia after spondylolisthesis correction surgery. *J Clin Anesth*. 2020;57(February 2019):77-8. doi: <https://doi.org/10.1016/j.jclinane.2019.03.015>
40. Yayik AM, Cesur S, Ozturk F, Ahiskalioglu A, Ay AN, Celik EC, et al. Postoperative analgesic efficacy of the ultrasound-guided erector spinae plane block in patients undergoing lumbar spinal decompression surgery: a randomized controlled study. *World Neurosurg*. 2020;126:e779-85. doi: <https://doi.org/10.1016/j.wneu.2019.02.149>
41. Singh S, Choudhary NK, Lalin D, Verma VK. Bilateral ultrasound-guided erector spinae plane block for postoperative analgesia in lumbar spine surgery: a randomized control trial. *J Neurosurg Anesth*. 2020;32(4):330-4. doi: <http://www.doi.org/10.1097/ANA.0000000000000603>
42. Qiu Y, Zhang T, Hua Z. Erector spinae plane block for lumbar spinal surgery: a systematic review. *J Pain Res*. 2020;13:1611-9. doi: <http://doi.org/10.2147/JPR.S256205>
43. Aksu C, Kus A, Yorukoglu H, Tor Kilic C, Gurkan Y. Analgesic effect of the bi-level injection erector spinae plane block after breast surgery: A randomized controlled trial. *Agri Pain*. 2019;31:132-7. doi: <http://www.doi.org/10.14744/agri.2019.61687>
44. Swisher MW, Wallace AM, Sztain JF, Said ET, Khatibi B, Abanobi M, et al. Erector spinae plane versus paravertebral nerve blocks for postoperative analgesia after breast surgery: a randomized clinical trial. *Reg Anesth Pain Med*. 2020;0(2020):1-7. doi: <http://www.doi.org/10.1136/rapm-2019-101013>
45. Gürkay Y, Aksu C, Ku A, Yörüko UH. Erector spinae plane block and thoracic paravertebral block for breast surgery compared to IV-morphine: A randomized controlled trial. *J Clin Anesth*. 2020;59:84-8. doi: <https://doi.org/10.1016/j.jclinane.2019.06.036>
46. Gürkay Y, Aksu C, Ku A, Yörüko UH, Cennet TK. Ultrasound guided erector spinae plane block reduces postoperative opioid consumption following breast surgery: A randomized controlled study. *J Clin Anesth*

- J. 2018;50(April):65-8. doi: <https://doi.org/10.1016/j.jclinane.2018.06.033>
47. Leong RW, Tan ESJ, Wong SN, Tan KH, Liu CW. Efficacy of erector spinae plane block for analgesia in breast surgery: a systematic review and meta-analysis. *Anaesthesia*. 2020;1-10. doi: <http://www.doi.org/10.1111/anae.15164>
48. Altıparmak B, Korkmaz M, İhsan A, Turan M. Comparison of the effects of modified pectoral nerve block and erector spinae plane block on postoperative opioid consumption and pain scores of patients after radical mastectomy surgery: A prospective, randomized, controlled trial. *J Clin Anesth*. 2019;54:61-5. doi: <https://doi.org/10.1016/j.jclinane.2018.10.040>
49. Gad K, Abdallah A, Abdelkhalek M, Abdelaziz M. Ultrasound-guided erector spinae plane block compared to modified pectoral plane block for modified radical mastectomy operations. *Anesth Essays Res*. 2019;13(2):334-9. doi: http://www.doi.org/10.4103/aer.AER_77_19
50. Sinha C, Kumar A, Kumar A, Prasad C, Priya D. Pectoral nerve versus erector spinae block for breast surgeries: A randomised controlled trial. *Indian J Anaesth*. 2019;63:617-22. doi: https://doi.org/10.4103/ija.IJA_163_19
51. El Ghamry MR, Amer AF. Role of erector spinae plane block versus paravertebral block in pain control after modified radical mastectomy. A prospective randomised trial. *Indian J Anaesth [Internet]*. 2019;63:1008-14. doi: https://doi.org/10.4103/ija.IJA_310_19
52. Moustafa M, Alabd A, Ahmed A, Deghidy E. Erector spinae versus paravertebral plane blocks in modified radical mastectomy: Randomised comparative study of the technique success rate among novice anaesthesiologists. *Indian J Anaesth*. 2020;64(1):49-54. doi: http://www.doi.org/10.4103/ija.IJA_536_19
53. Sharma S, Arora S, Jafra A, Singh G. Efficacy of erector spinae plane block for postoperative analgesia in total mastectomy and axillary clearance: A randomized controlled trial. *Saudi J Anesth*. 2020;14(2):1-6. doi: http://www.doi.org/10.4103/sja.SJA_625_19
54. Singh S, Kumar G, Akhlleshwar. Ultrasound guided erector spinae plane block for postoperative analgesia in modified radical mastectomy: A randomised control study Address. *Indian J Anaesth*. 2019;63(3):42-6. doi: http://www.doi.org/10.4103/ija.IJA_758_18
55. Yao Y, Li H, He Q, Chen T, Wang Y, Zheng X. Efficacy of ultrasound-guided erector spinae plane block on postoperative quality of recovery and analgesia after modified radical mastectomy: randomized controlled trial. *Reg Anesth Pain Med*. 2019;0:1-5. doi: <http://www.doi.org/10.1136/rapm-2019-100983>
56. Altıparmak B, Tokar M, Uysal A, Demirbilek S. Comparison of the efficacy of erector spinae plane block performed with different concentrations of bupivacaine on postoperative analgesia after mastectomy surgery: randomized, prospective, double blinded trial. *BMC Anesthesiol*. 2019;19(32):1-9. doi: <https://doi.org/10.1186/s12871-019-0700-3>
57. Oksuz G, Bilgen F, Arslan M, Duman Y. Ultrasound-guided bilateral erector spinae block versus tumescent anesthesia for postoperative analgesia in patients undergoing reduction mammoplasty: a randomized controlled study. *Aesth Plast Surg*. 2019;43:291-6. doi: <https://doi.org/10.1007/s00266-018-1286-8>
58. Tulgar S, Selvi O, Kapakli MS, Reports C. Erector spinae plane block for different laparoscopic abdominal surgeries: case series. *Case Rep Anesthesiol*. 2018;2018:8-10. doi: <http://www.doi.org/10.1155/2018/3947281>
59. Altıparmak B, Korkmaz M, İhsan A, Kuşçu Y. Ultrasound-guided erector spinae plane block versus oblique subcostal transversus abdominis plane block for postoperative analgesia of adult patients undergoing laparoscopic cholecystectomy: Randomized, controlled trial. *J Clin Anesth*. 2019;57 (December 2018):31-6. doi: <https://doi.org/10.1016/j.jclinane.2019.03.012>
60. Tulgar S, Kapakli MS, Kose HC, Senturk O, Selvi O, Serifsoy TE, et al. Evaluation of ultrasound-guided erector spinae plane block and oblique subcostal transversus abdominis plane block in laparoscopic cholecystectomy: randomized, controlled, prospective study. *Anesth Essays Res*. 2019;13(1):50-6. doi: http://www.doi.org/10.4103/aer.AER_194_18
61. Tulgar S, Sertan M, Senturk O, Selvi O, Ercan T. Evaluation of ultrasound-guided erector spinae plane block for postoperative analgesia in laparoscopic cholecystectomy: A prospective, randomized, controlled clinical trial. *J Clin Anesth*. 2018;49(April):101-6. doi: <https://doi.org/10.1016/j.jclinane.2018.06.019>
62. Kwon H, Kim D, Jeong S, Choi KT, Park S, Kwon H, et al. Does erector spinae plane block have a visceral analgesic effect?: a randomized controlled trial. *Sci Rep*. 2020;10(8389):1-8. doi: <http://dx.doi.org/10.1038/s41598-020-65172-0>
63. Altınpulluk EY, Simón DG. Erector spinae plane block for analgesia after lower segment caesarean section: Case report. *Rev Esp Anestesiología Reanim*. 2020;65(5):284-6. doi: <https://doi.org/10.1016/j.redar.2017.11.006>
64. Restrepo-Garcés CE, Chin KJ, Hons M, Suárez P, Díaz A. Bilateral continuous erector spinae plane block contributes to effective postoperative analgesia after major open abdominal surgery: a case report. *A A Case Reports*. 2017;9(11):319-21. doi: <http://www.doi.org/10.1213/XAA.0000000000000605>
65. Gaio-Lima C, Costa CC, Moreira JB, Lemos TS, Trindade HL. Continuous erector spinae plane block for analgesia in pediatric thoracic surgery: A case report. *Rev Esp Anestesiología Reanim*. 2020;65(5):287-90. doi: <https://doi.org/10.1016/j.redar.2017.11.010>
66. Nardiello MA, Herlitz M. Bilateral single shot erector spinae plane block for pectus excavatum and pectus carinatum surgery in 2 pediatric patients. *Rev Esp Anestesiología Reanim*. 2018;65(9):530-3. doi: <https://doi.org/10.1016/j.redar.2018.04.006>
67. Aksu C, Gurkan Y. Ultrasound-guided bilateral erector spinae plane block could provide effective postoperative analgesia in laparoscopic cholecystectomy in paediatric patients. *Anaesth Crit Care Pain Med*. 2020;38(2019):87-8. doi: <https://doi.org/10.1016/j.accpm.2018.03.008>
68. Hernández MA, Palazzi L, Lapalma J, Cravero J. Erector spinae plane block for inguinal hernia repair in preterm infants. *Pediatr Anesth*. 2018;00(December 2017):2017-8. doi: <https://doi.org/10.1111/pan.13325>
69. Tulgar S, Senturk O. Ultrasound guided Erector Spinae Plane block at L-4 transverse process level provides effective postoperative analgesia for total hip arthroplasty. *J Clin Anesth*. 2018;44:68. doi: <https://doi.org/10.1016/j.jclinane.2017.11.006>
70. Bugada D, Zarcone AG, Manini M, Lorini LF. Continuous erector spinae block at lumbar level (L4) for prolonged postoperative analgesia after

- hip surgery. *J Clin Anesth.* 2018;52:24-5. doi: <https://doi.org/10.1016/j.jclinane.2018.08.023>
71. Darling CE, Pun SY, Caruso TJ, Tsui BCH. Successful directional thoracic erector spinae plane block after failed lumbar plexus block in hip joint and proximal femur surgery. *J Clin Anesth.* 2018;49(April 2018):1-2. doi: <https://doi.org/10.1016/j.jclinane.2018.05.002>
 72. Balaban O, Aydın T. Lumbar erector spinae plane catheterization for continuous postoperative analgesia in total knee arthroplasty: A case report. *J Clin Anesth.* 2019;55:138-9. doi: <https://doi.org/10.1016/j.jclinane.2018.12.017>
 73. Ueshima H. Pneumothorax after the erector spinae plane block. *J Clin Anesth.* 2018;48(April 2018):12. doi: <https://doi.org/10.1016/j.jclinane.2018.04.009>
 74. Elkoundi A, Eloukkal Z, Bensghir M, Belyamani L. Priapism following erector spinae plane block for the treatment of a complex regional pain syndrome. *Am J Emerg Med.* 2019;37(4):796.e3-796.e4. doi: <https://doi.org/10.1016/j.ajem.2019.01.012>
 75. Selvi O, Tulgar S. Ultrasound guided erector spinae plane block as a cause of unintended motor block. *Rev Esp Anesthesiol Reanim.* 2018;65(10):589-92. doi: <https://doi.org/10.1016/j.redar.2018.05.009>
 76. Sondekoppam RV, Tsui BCH. Factors associated with risk of neurologic complications after peripheral nerve blocks. *Anesth Analg.* 2017;124(2):645-60. doi: <http://www.doi.org/10.1213/ANE.0000000000001804>
 77. Tulgar S, Selvi O. Ultrasound-guided erector spinae plane block: indications, complications, and effects on acute and chronic pain based on a single-center experience. *Cureus.* 2019;11(1):e3815. doi: <http://www.doi.org/10.7759/cureus.3815>