



# Colombian Journal of Anesthesiology

Revista Colombiana de Anestesiología

www.revcolanest.com.co

OPEN

 Wolters Kluwer

## Successful rescue with videolaryngoscopy after failed fibroscopy in anticipated difficult airway: case series

## Rescate exitoso con videolaringoscopia luego de fibroscopia fallida en vía aérea difícil anticipada: serie de casos

Daniela González-Giraldo<sup>a</sup>, Carlos Eriel Largo-Pineda<sup>b</sup>,  
Mario Andrés Zamudio-Burbano<sup>a,c,d</sup>

<sup>a</sup> Medical School, Universidad de Antioquia, Medellín, Colombia

<sup>b</sup> Universidad Militar Nueva Granada, Bogotá, Colombia

<sup>c</sup> IPS Universitaria, Medellín, Colombia

<sup>d</sup> EVA-La CLASA member.

**Keywords:** Airway management, Case report, Failed rescue in health care, Fiber optics, Tracheal intubation

**Palabras clave:** Fibras ópticas, Fracaso de rescate en atención a la salud, Intubación traqueal, Manejo de vía aérea, Reporte de casos

### Abstract

**Introduction:** In the management of the anticipated difficult airway (DA), awake intubation is the strategy of choice. In this context, flexible fibroscopy is the tool most widely used as the first choice. However, there is always the rare case where it may fail.

**Important findings:** Six successful rescue cases using videolaryngoscopy following failed fibroscopy in patients with anticipated DA, and 1 case of rescued extubation of an airway previously secured with fiberoptic bronchoscopy.

**Conclusion:** Videolaryngoscopy may be an adequate tool to use as a backup plan for the management of an anticipated DA.

### Resumen

**Introducción:** En el manejo de vía aérea difícil anticipada la estrategia de elección es la intubación con el paciente despierto. En este contexto, la fibroscopia flexible es la herramienta más utilizada como plan A; sin embargo, en raras ocasiones puede fallar.

**Hallazgos importantes:** Se presentan seis casos de rescates exitosos con videolaringoscopia luego de fibroscopia fallida en pacientes con vía aérea difícil anticipada, y un caso de rescate de extubación de vía aérea asegurada previamente con fibrobroncoscopio.

**Conclusión:** La videolaringoscopia puede ser una adecuada herramienta como plan B para el manejo de la vía aérea difícil anticipada.

### Introduction

The classical definition of a difficult airway (DA) of the American Society of Anesthesiologists is the clinical situation in which a conventionally trained anesthetist has difficulty ventilating the patient with a facial mask, tracheal intubation, or both.<sup>1</sup> When it is identified before induction, it is classified as anticipated DA (ADA) and it constitutes a scenario of great concern in the practice of

How to cite this article: González-Giraldo D, Largo-Pineda CE, Zamudio-Burbano MA. Successful rescue with videolaryngoscopy after failed fibroscopy in anticipated difficult airway: case series. Colombian Journal of Anesthesiology. 2020;48:96-99.

Read the Spanish version of this article at: <http://links.lww.com/RCA/A921>.

Copyright © 2020 Sociedad Colombiana de Anestesiología y Reanimación (S.C.A.R.E.). Published by Wolters Kluwer. This is an open access article under the CC BY-NC-ND license (<http://creativecommons.org/licenses/by-nc-nd/4.0/>).

Correspondence: Anesthesia Service, Hospital Universitario San Vicente Fundación, Calle 64 No. 51D-154, Medellín, Colombia.  
E-mail: [mario.zamudio@udea.edu.co](mailto:mario.zamudio@udea.edu.co) (M.A. Zamudio-Burbano)

Colombian Journal of Anesthesiology (2020) 48:2

<http://dx.doi.org/10.1097/CJ9.0000000000000139>

anesthesia because of its association with high morbidity and mortality in failure cases.<sup>2</sup>

There is agreement as to the standard of care for this situation, consisting of management of the airway with the patient awake or on spontaneous ventilation,<sup>3</sup> mainly in the trauma setting<sup>4,5</sup> and in critically ill patients.<sup>6,7</sup> Although recognized as versatile alternative tools, flexible fibroscopy, and videoendoscopy intubation may fail.

There is a paucity of evidence regarding rescue videolaryngoscopy in the setting of ADA. Only a combined approach using fibrolaryngoscopy and videolaryngoscopy is described in the setting of blunt airway trauma.<sup>8</sup> We report 7 cases in which rescue angled blade videolaryngoscopy was used successfully following failed flexible fibroscopy in awake patients with ADA.

### Clinical cases

All the cases included in this report were diagnosed as ADA and subjected to awake intubation with flexible fibroscopy. Sedation was based on titrated doses of remifentanyl between 0.1 and 0.3  $\mu\text{g}/\text{kg}/\text{min}$ , associated with a spray as you go technique with 2% lidocaine instillation through the working channel with doses ranging between 200 and 450 mg and topical application of 50  $\mu\text{g}$  of oxymetazoline through both nostrils, plus local anesthetic applied on the anatomical fibroscope entry site (oropharynx or nasopharynx with 10% lidocaine spray).

Table 1 shows a summary of the baseline characteristics of the patients and the rescue technique following failed fibroscopy.

### Discussion

Patients with DA are one of the biggest challenges for the anesthetist. Access to airway in the awake patient using techniques such as fiberoptic bronchoscopy (FOB) has been recognized as the gold standard for the management of patients with ADA, it being the most studied and recommended option.<sup>2,9</sup> However, there are downsides to this technique, including the training required, the skills needed to identify airway structures, cost, the need for frequent maintenance, and the fragility of the equipment.

Failure has been reported in conditions such as obstruction for nasal passage, posterior pharyngeal wall tumors, presence of blood and secretions, airway trauma, complete airway obstruction, distorted anatomy, or technical limitations preventing access to the glottic cavity with the endotracheal tube.<sup>10-13</sup> These situations require immediate change of plan to establish access for intubation.<sup>14</sup>

Alternative plans described include translaryngeal accesses for rescue, although those techniques may have limitations due to lack of anesthetist experience, morbidity, late complications, and the time required to perform them. Reported success of the translaryngeal access performed by anesthetists in emergency situations is

quite low, and it is accomplished in only 36% of the procedures. Series like the National Audit Project 4 report a failure rate as high as 60%.<sup>15</sup> For this reason, the open technique suggested by the Difficult Airway Society is recommended at present, using scalpel blade, bougie, and a No. 6.0 endotracheal tube; it requires less training and shorter performance time, and success rates are higher.<sup>16</sup>

Likewise, other alternative anesthetic options after failed fiber-optic intubation are described, including blind intubation through supraglottic intubation devices, guide wire-aided blind intubation, and videolaryngoscopy. Over the last few years, the latter technique has gained acceptance for ADA patients, with results equivalent to those obtained with fibroscopy techniques, offering the possibility of securing the airway faster. It is estimated that an anesthetist must perform 25 intubations with FOB to acquire a basic learning curve compared to only 1 to 6 video laryngoscopy (VL) intubations to achieve the same skill level.<sup>17</sup>

In 2018, a meta-analysis of 429 patients compared VL vs FOB for awake intubation. This study showed shorter intubation time using the VL technique (45 seconds) as compared to FOB, but no differences in term of overall success rates, patient satisfaction, or adverse effects with the 2 strategies.<sup>17</sup>

Awake fibroscopy failure and loss of a previously secured airway by trained personnel are rare. The 7 cases presented here represent 0.76% of patients seen by the airway team at Universidad de Antioquia (921) over the past 3 years.

The causes of failure are summarized in Table 1. The authors believe that they were due to mechanical limitations associated with the anterior curvature (cases 3, 4, 5, 6, and 7) (Fig. 1). All of these were solved using VL, allowing glottic aperture and reducing neck flexion curvature (Fig. 2). On the other hand, given that tracheal tube insertion in videolaryngoscopy is separate from visualization (non-channeled blades), tracheal tubes of different sizes may be readily exchanged, unlike what happens with the fibroscopy technique which requires new exploration with every change of tube size.

Since VL intubation time is shorter than with fibroscopy—reported as at least 10 minutes in expert hands—VL may offer more successful rescue in cases of extubation due to position changes or inadequate fixation (case 2).

### Conclusion

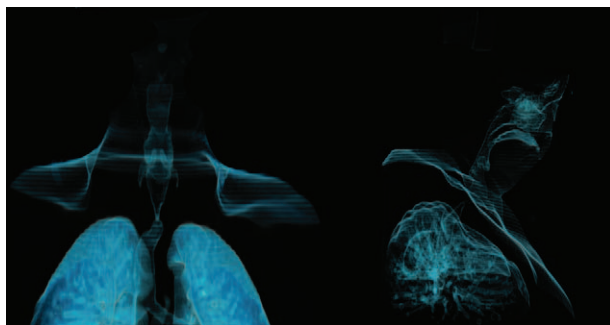
The conclusion of this case series is that VL could be a great option in ADA for awake intubation following failed FOB intubation. Advantages previously reported for VL are highlighted, including improved visual field, the ability to use different tubes and exchange them during the procedure without losing visualization, faster tracheal tube exchanges, as well as tissue traction which increases glottic aperture in cases of abnormal airway anatomy.

Our study is limited in that it is a case series; however, it is considered novel given that fibroscopy failure in expert hands is infrequent. We believe that anesthetists must

**Table 1. Baseline characteristics of the patients and rescue technique.**

Case	Gender	Age	Diagnosis	Physical examination	Rescue technique	Cause of failure
1	Female	31	C1/C2 joint dislocation	70kg, Height 165 cm, OA: >3 cm, Mallampati: I, TMD: >6 cm, SMD: >12 cm, ULBT: I, BT: Class I, with LCM	C-MAC Storz D-Blade	Marked neck flexion preventing tracheal tube passage
2	Male	67	Morbid obesity	140 kg, Height 162 cm, OA: >3 cm, Mallampati: IV, TMD: not measured due to neck circumference, SMD: >12 cm, ULBT: I, BT: Class I, morbid obesity, with STOP BANG 6/8	King Vision channeled blade	Extubation at the time of position change
3	Female	81	Supraglottic mass obliterating the epiglottis	58 kg, Height 158 cm, OA: 2–3 cm, Mallampati: II, TMD: >6 cm, SMD: >12 cm, ULBT: I, BT: Class I, with LCM, CAT scan showing obliterating mass in the airway	AP Advance MAC 3	Failure to pass the fibroscope due to anatomic alteration
4	Female	25	History of laryngeal surgery	60 kg, Height 160 cm, OA: >3 cm, Mallampati: I, TMD: >6 cm, SMD: >12 cm, ULBT: I, BT: Class I, with LCM and laryngeal distortion	AP Advance angled non-channeled blade	Failure to pass the fibroscope due to anatomic alteration
5	Male	45	80% Glottic stenosis	OA: >3 cm, Mallampati: III, TMD: >6 cm, SMD: >12 cm, 90 kg, Height 176 cm, no LCM	C-MAC Storz D-Blade	Failure to pass the fibroscope due to mechanical limitation
6	Male	60	Subglottic obstruction 90%	100 kg, Height 170 cm, OA: >3 cm, Mallampati: III, TMD: >6 cm, SMD: >12 cm, ULBT: II, BT: Class I, no LCM, reconstruction in <a href="#">Fig. 1</a>	C-MAC Storz D-Blade	Failure to pass the fibroscope due to mechanical limitation
7	Male	47	Morquio syndrome with cervical instability	50 kg, Height 155 cm, OA: 2 cm, Mallampati: IV, TMD: <6 cm, SMD: <12 cm, ULBT: III, BT: Class I, with cervical limitation	C-MAC Storz D-Blade ( <a href="#">Fig. 2</a> )	Failure to pass the tracheal tube over the fibroscope due to mechanical limitation

BT: bite type, CAT: cranial axial tomography, LCM: limitation of cervical motion, OA: Oral Aperture, SMD: sternomental distance, TMD: thyromental distance, ULBT: upper lip bite test.  
Source: Authors.



**Figure 1. Three-dimensional reconstruction of the airway (case 6 with 90% subglottic stenosis).**  
Source: Authors.

train in the use of videolaryngoscopy in ADA, and prepare clear plans before approaching complex patients, thus improving safety in anesthesia.

Finally, further studies are warranted in ADA in order to determine which type of videolaryngoscope is the most suitable in this context and when it should be used as the first choice, even before, or together with, flexible fibroscopy.

### Ethical responsibilities

**Human and animal protection:** The authors declare that all the procedures were performed in accordance with the

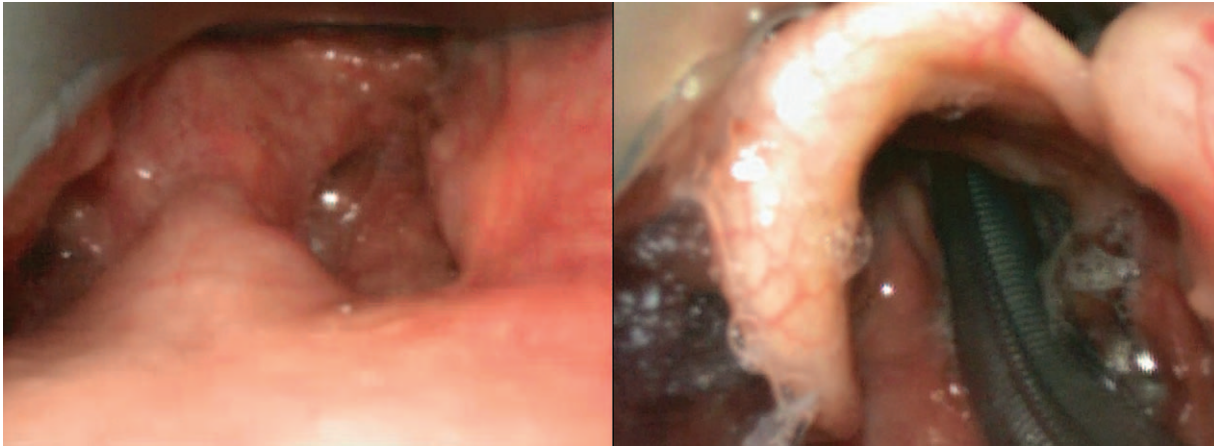

Figure 2. Rescue with D-Blade videolaryngoscopy in patients with de Morquio syndrome.  
Source: Authors.

ethical standards of the responsible human experimentation committee, and the World Medical Association and the Declaration of Helsinki.

**Data confidentiality:** The authors declare that they followed the protocols of their center of practice regarding disclosure of patient data.

**Right to privacy and informed consent:** The authors declare that they obtained informed consents from the patients and/or subjects mentioned in the article. The relevant documents are kept by the corresponding author.

Each of the participants were informed before the procedure was carried out in relation to the alternatives and difficult airway devices including their risks, benefits and the need to perform such approaches under grade I sedation. Each of them filled out the informed consent of the difficult airway group of the Universidad de Antioquia prior to the anesthetic procedure. Document is attached. No other resolutions or approvals were required as it was a case series review, where clinical plans were based on international scientific recommendations without the need to intervene in other options than those established in the literature.

### Acknowledgments

The authors are grateful to Universidad de Antioquia, San Vicente Fundación University Hospital, and Clínica León XIII University Clinic for their support for the difficult airway program.

### Funding

The authors declare having received no funding.

### Conflicts of interest

The authors have no conflicts of interest to disclose.

### References

1. Apfelbaum JL, Hagberg CA, Caplan RA, et al. Practice guidelines for management of the difficult airway: an updated report by the American Society of Anesthesiologists Task Force on Management of the Difficult Airway. *Anesthesiology* 2013;118:251-270.
2. Langeron O, Bourgain JL, Francon D, et al. Difficult intubation and extubation in adult anaesthesia. *Anaesth Crit Care Pain Med* 2018;37:639-651.
3. Vallejo-Villalobos ML. Airway in the patient with trauma. *Rev Mex Anestesiol* 2018;41 (s1):203-210.
4. Walrath BD, Harper S, Barnard E, et al. Airway management for trauma patients. *Mil Med* 2018;183 (suppl. 2):29-31.
5. Kovacs G, Sowers N. Airway management in trauma. *Emerg Med Clin North Am* 2018;36:61-84.
6. Higgs A, Cook TM, McGrath BA. Airway management in the critically ill: the same, but different. *Br J Anaesth* 2016;117:i5-i9.
7. Lapinsky SE. Endotracheal intubation in the ICU. *Crit Care* 2015;19:258.
8. Mercer SJ, Jones CP, Bridge M, et al. Systematic review of the anaesthetic management of non-iatrogenic acute adult airway trauma. *Br J Anaesth* 2016;117:i49-i59.
9. Flin R, Fioratou E, Frerk C, et al. Human factors in the development of complications of airway management: preliminary evaluation of an interview tool. *Anaesthesia* 2013;68:817-825.
10. Watson NC, Hokanson M, Maltby JR, et al. The intubating laryngeal mask airway in failed fiberoptic intubation. *Can J Anaesth* 1999;46:376-378.
11. Wulf H, Brinkmann G, Rautenberg M. Management of the difficult airway. A case of failed fiberoptic intubation. *Acta Anaesthesiol Scand* 1997;41:1080-1082.
12. Naithani M, Jain A. Failed nasal intubation after successful flexible bronchoscopy: guide wire to the rescue. *J Anaesthesiol Clin Pharmacol* 2011;27:395-397.
13. Huitink JM, Zijp L. Laryngeal radiation fibrosis: a case of failed awake flexible fiberoptic intubation. *Case Rep Anesthesiol* 2011;2011:878910.
14. Law JA, Morris IR, Brousseau PA, et al. The incidence, success rate, and complications of awake tracheal intubation in 1,554 patients over 12 years: an historical cohort study. *Can J Anaesth* 2015;62:736-744.
15. Cook TM, Woodall N, Frerk C, et al. Major complications of airway management in the UK: results of the Fourth National Audit Project of the Royal College of Anaesthetists and the Difficult Airway Society. Part 1: Anaesthesia. *Br J Anaesth* 2011;106:617-631.
16. Frerk C, Mitchell VS, McNarry AF, et al. Difficult Airway Society 2015 guidelines for management of unanticipated difficult intubation in adults. *Br J Anaesth* 2015;115:827-848.
17. Alhomary M, Ramadan E, Curran E, et al. Videolaryngoscopy vs. fiberoptic bronchoscopy for awake tracheal intubation: a systematic review and meta-analysis. *Anaesthesia* 2018;73:1151-1161.