



# Colombian Journal of Anesthesiology

*Revista Colombiana de Anestesiología*

www.revcolanest.com.co

OPEN

Wolters Kluwer

## Erector spinae plane (ESP) block for postoperative analgesia in total radical mastectomy: case report

### Bloqueo del elevador de la espina (ESP) para analgesia posoperatoria en mastectomía radical total: reporte de caso

**Keywords:** Pain, Postoperative, Analgesia, Mastectomy, Case Reports, Nerve Block

**Palabras clave:** Dolor Posoperatorio, Analgesia, Mastectomía, Informes de Casos, Bloqueo Nervioso

Elba Orozco<sup>a,b</sup>, Rafael Enrique Serrano<sup>a,b</sup>, Viviana Pahola Rueda-Rojas<sup>c</sup>

<sup>a</sup> Hospital Universitario de Santander, Bucaramanga, Colombia

<sup>b</sup> Anaesthesia and Resuscitation Graduate Program, Universidad Industrial de Santander, Bucaramanga, Colombia

<sup>c</sup> Third year resident of Anaesthesia and Resuscitation, Universidad Industrial de Santander, Bucaramanga, Colombia.

#### Abstract

**Case report:** A 50-year-old female patient with an 8-year history of a mass in the right breast which has undergone rapid progressive growth, involving the entire breast, over the past 7 months, diagnosed as a phyllodes tumor. Simple right mastectomy with axillary lymph node dissection and pectoralis major fascia resection were performed under general anesthesia. Ultrasound-guided erector spinae plane block was performed for postoperative analgesia, with excellent response up to 18 hours following the procedure, and no need for additional opioids. There were no adverse effects or complications associated with the block.

**Conclusion:** Ultrasound-guided erector spinae block is a fast and safe procedure that may be used as a valuable adjunct to ensure postoperative analgesia in radical mastectomy cases, which pose a challenge in terms of pain control. Moreover, it offers an advantage in terms of reduced opioid requirement in these patients.

#### Resumen

**Caso clínico:** Se presenta el caso de una paciente de 50 años con cuadro clínico de 8 años de evolución de masa en mama derecha la cual en los últimos 7 meses muestra un crecimiento rápido y progresivo que ocupa toda la mama, hacen diagnóstico de tumor filloides. Realizan mastectomía derecha simple más vaciamiento ganglionar axilar y resección de fascia pectoral mayor bajo anestesia general. Se efectúa bloqueo del elevador de la espina guiado por ultrasonido con fines analgésicos en el posoperatorio, obteniéndose una excelente respuesta hasta 18 horas posterior al procedimiento, sin necesidad de consumo de opioides, no se registraron efectos adversos o complicaciones relacionadas con el bloqueo.

**Conclusiones:** El bloqueo del elevador de la espina ecoguiado es un procedimiento rápido y seguro que puede ser una herramienta valiosa para asegurar la analgesia posoperatoria en mastectomías radicales que generan un desafío en control del dolor, además de la ventaja de disminución de consumo de opioides en estas pacientes.

How to cite this article: Orozco E, Serrano RE, Rueda-Rojas VP. Erector spinae plane (ESP) block for postoperative analgesia in total radical mastectomy: case report. Rev Colomb Anesthesiol. 2018;46:66-68.

Consulte la versión en español de este artículo en <http://links.lww.com/RCA/A40>.

Copyright © 2018 Sociedad Colombiana de Anestesiología y Reanimación (S.C.A.R.E.). Published by Wolters Kluwer. This is an open access article under the CC BY-NC-ND license (<http://creativecommons.org/licenses/by-nc-nd/4.0/>).

Correspondence: Cra 36 # 36-56, Apartamento 1106 Edificio Prado Onix, Bucaramanga, Colombia. E-mail: [viparuro11@hotmail.com](mailto:viparuro11@hotmail.com)

Rev Colomb Anesthesiol (2018) 46:Supp

<http://dx.doi.org/10.1097/CJ9.0000000000000048>

## Introduction

Postoperative pain control in breast cancer surgery has become one of the most important goals for anesthetists. Multiple tools are available for achieving pain control, including intraoperative multimodal analgesia and regional techniques (interpectoral block (PEC 1) and pectoral nerv block (PEC 2), cutaneous branches block of the intercostal nerves (BRILMA), intercostal blocks, or paravertebral blocks). Ultrasound-guided erector spinae plane (ESP) block is an innovative, easy, safe, and fast technique that can provide good analgesia with a reduced need for opioid use. We present the case of a patient taken to mastectomy in whom ESP block for postoperative analgesia was performed.

## Clinical case

A 50-year-old female patient, housewife, was admitted in the oncologic gynecology outpatient clinic of Santander University Hospital. The patient had an 8-year history of a mass in the right breast, initially managed as a fibroadenoma, which has been growing rapidly and progressively over the past 7 months, involving the entire breast, and associated with intense, debilitating pain. She brings a biopsy report of November 2016 with a result of a phyllodes tumor and no other remarkable prior findings, and a normal cervical cytology report of March 2017. Laboratory tests on admission included whole blood count showing a hemoglobin of 11.2 mg/dL, with no leukocytosis or neutrophilia. On physical examination, the patient is found in an acceptable general condition, a weight of 62 kg, with the right breast completely displaced due to a large multilobulated tumor mass of approximately 20 cm in diameter (Fig. 1), with areas of ulceration and not active bleeding. Because of its size, the mass limits ambulation

and is a source of constant pain. The patient was admitted for urgent mastectomy with flaps.

Two days later, the patient was transferred to the operating room for a right mastectomy plus axillary lymph node dissection. Basic monitoring was performed using a 3-channel electrocardiogram monitor, non-invasive blood pressure monitoring, and saturation; hypothermia was controlled using a thermal blanket. The Bispectral Index (BIS) was used for neurologic monitoring. Intravenous anesthesia induction was started with fentanyl 200 µg, propofol 120 mg, rocuronium 36 mg, and maintenance was achieved with balanced general anesthesia using sevoflurane Minimum alveolar concentration (MAC) 0.6 to 0.7, remifentanyl 0.15 to 0.2 µg/kg/minute, with dynamic settings for maintaining a BIS of 40 to 45. The gynecological oncology team performed right simple mastectomy plus axillary lymph node dissection and pectoralis major fascia resection and obtained a specimen of the right breast weighing 5020 g. During the procedure, the patient received dexamethasone 8-mg Intravenous (IV) for nausea and vomiting prevention, dipirone 2.5 g and diclofenac 75-mg IV. At the end of the procedure, with the patient still under general anesthesia, the anesthesia team in charge of the case proceeded to the ESP block. The patient was placed on left lateral decubitus and, following asepsis and anti-sepsis, T6 to T7 and right paravertebral ultrasound was performed using a high-frequency linear probe, to identify the anatomy: (1) skin, (2) subcutaneous cellular tissue, (3) trapezius muscle, (4) rhomboid major muscle, (5) erector spinae muscle, and (6) transverse process (Fig. 2). A 50-mm echo-sensitive needle was placed through an in-plane cephalocaudal approach up to the erector spinae muscle, and bupivacaine with 0.25% epinephrine and 0.5% lidocaine was administered (total volume 20 mL), achieving satisfactory erector spinae hydrodissection. The patient was also given intravenous

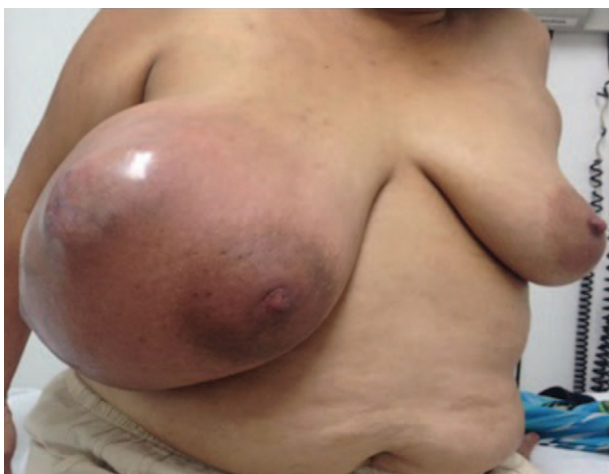

Figure 1. Breast mass pre-operatively.  
Source: Authors.

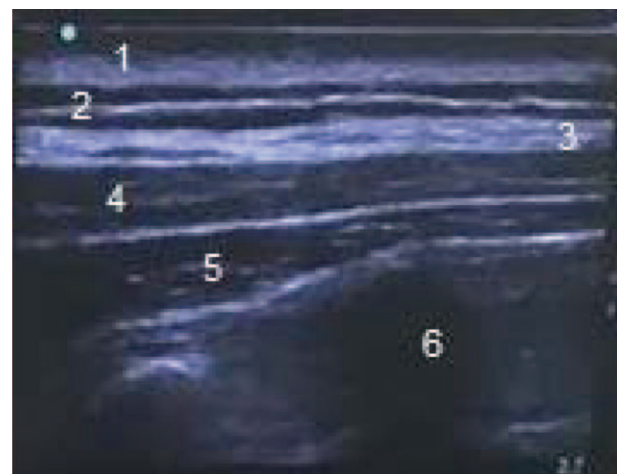


Figure 2. Ultrasound image of ESP block. ESP=erector spinae plane.  
Source: Authors.

**Table 1. Result of patient follow-up**

Case	Sensory block area	Pain intensity assessment VAS					Use of morphine PCA
		Hours					
		4	12	18	24	30	
1	T6–T12	0	0	1	1	2	1mg in 30hours

PCA=patient controlled analgesia; VAS=visual scale.  
Source: Authors.

morphine patient controlled analgesia for rescue analgesia. Assessment 4 hours later found an area of anesthesia comprised by the right anterior hemithorax and axillary region and anesthesia from T4 to T12 in the posterior region. Pain assessment was performed over a 30-hour period using the analog visual scale (Table 1).

## Discussion

This technique was originally described in 1905 by Sellheim and reintroduced into clinical practice by Eason and Wyatt in 1979.<sup>1</sup> There is an ongoing search for cost-effective strategies for postoperative pain control or for the control of acute or chronic pain syndromes.<sup>2</sup>

ESP block is an innovative technique in which local anesthetic is placed between the deep fascial plane of the erector spinae muscle and superficial to the tip of the transverse process.<sup>3</sup> Despite being a new technique, it has been shown to be useful in the treatment of acute or chronic conditions like chest, abdominal, and pelvic pain.<sup>4</sup>

Results in our patient were found to be similar to those of other publications describing total anesthesia in the first 12 hours, and even up to 36 hours of chronic neuropathic chest pain<sup>4</sup>; moreover, this block offers immediate pain relief.

Among peripheral blocks, ESP is currently used as first-line postoperative analgesia in thoracotomy.<sup>5</sup> There are no studies in mastectomy, and it would be important to conduct further studies with a larger sample to replicate our results.

Based on our findings, ESP block may be recommended as an option or adjunct for pain management in this very important group of patients in our population.

## Conclusion

ESP block is a safe, innovative strategy that is easy to perform and ensures good postoperative analgesia in radical mastectomy, reducing opioid requirements. It

offers good pain management, contributing to faster patient recovery.

In this patient, the analgesic strategy using erector spinae block was efficient and provided 30 hours of good analgesia with the need for only 1 mg of morphine over 28 hours, with no adverse effects or complications. These data suggest that ESP is a useful, simple, and fast strategy for postoperative pain management in mastectomy cases, although not many articles have been published to date on this topic.

## Acknowledgments

We wish to thank Universidad Industrial de Santander and Hospital Universitario de Santander for making it possible for us to conduct our research.

## Ethical responsibilities

**Protection of human and animal subjects.** The authors declare that the procedures followed were in accordance with the regulations of the relevant clinical research ethics committee and with those of the Code of Ethics of the World Medical Association (Declaration of Helsinki).

**Confidentiality of data.** The authors declare that they have followed the protocols of their work center on the publication of patient data.

**Right to privacy and informed consent.** The authors have obtained the written informed consent of the patients or subjects mentioned in the article. The corresponding author is in possession of this document.

## Funding comment

The authors received no sponsorship for conducting this study.

## Conflicts of interest

The authors declare having no conflict of interest.

## References

1. Eason MJ, Wyatt R. Paravertebral thoracic block—a reappraisal. *Anaesthesia* 1979; 34:638–642.
2. Krediet AC, Moayeri N, van Geffen GJ, et al. Different approaches to ultrasound-guided thoracic paravertebral block: an illustrated review. *Anesthesiology* 2015; 123:459–474.
3. Hamilton DL, Manickam B. Erector spinae plane block for pain relief in rib fractures. *Br J Anaesth* 2017; 118:474–475.
4. Forero M, Adhikary SD, López H, et al. The erector spinae plane block: a novel analgesic technique in thoracic neuropathic pain. *Reg Anesth Pain Med* 2016; 41:621–627.
5. Forero M, Rajarathinam M, Adhikary S, et al. Continuous erector spinae plane block for rescue analgesia in thoracotomy after epidural failure: a case report. *AA Case Rep* 2017; 8:254–256.