



Colombian Journal of Anesthesiology

Revista Colombiana de Anestesiología

www.revcolanest.com.co

OPEN

Wolters Kluwer

Erector spinae plane block as a rescue analgesia technique in a patient with HeartMate 3 ventricular assist type device: case report

Bloqueo de plano del músculo erector de la espina como técnica analgésica de rescate en un paciente con asistencia ventricular tipo HeartMate 3: reporte de caso

Keywords: Heart-Assist Devices, Pain, Analgesia, Nerve Block, Pain, Postoperative

Palabras clave: Dispositivos para Soporte Cardíaco, Dolor, Analgesia, Bloqueo Nervioso, Dolor Posoperatorio

Lizette Benavides^a, Rubén Heredia^a, Luz J. Pacheco^b, Leonardo A. Salazar^c

^a Anesthesiology and Resuscitation Postgraduate Program, Department of Surgery, Universidad Industrial de Santander, Bucaramanga, Colombia

^b Cardiovascular Anesthesia, Department of Cardiovascular Surgery, Fundación Cardiovascular de Colombia, Floridablanca, Colombia.

^c Ecmo-Vad Group, Fundación Cardiovascular de Colombia, Floridablanca, Colombia.

Abstract

Introduction: Heart failure represents a public health problem involving high morbidity and mortality. For advanced stages of the disease the use of ventricular assist devices (VADs) has been implemented as destination therapy. The perioperative management of patients with VADs may result in multiple challenges, with optimal pain management being one of those challenges.

Objective: To describe the use of erector spinae plain (ESP) block as a rescue analgesia technique in a patient undergoing HeartMate 3 type VAD implantation.

Methods: Case report and subject review.

Results: The case discussed is a patient with ischemic cardiomyopathy and severe ventricular dysfunction, undergoing a HeartMate 3 type VAD implant as destination therapy, under general anesthesia and postoperative analgesia protocol with

fentanyl and acetaminophen. During the postoperative period the patient developed acute pain of severe intensity (visual analogue scale [VAS]: 8–10/10), that led to the use of a regional rescue technique—ESP block—that showed satisfactory results with optimal analgesia control (VAS: 1–3/10).

Conclusion: The ESP block was a safe and effective option as part of a postoperative analgesia strategy for a patient with a HeartMate 3 type VAD implant.

Resumen

Introducción: la insuficiencia cardíaca representa un problema de salud pública con alta morbimortalidad. En estadios avanzados se ha implementado el uso de dispositivos de asistencia ventricular (DAV) como terapia destino. El manejo perioperatorio de pacientes con DAV puede generar múltiples retos, dentro de los cuales se destaca el manejo óptimo del dolor.

How to cite this article: Benavides L, Heredia R, Pacheco LJ, Salazar LA. Erector spinae plane block as a rescue analgesia technique in a patient with HeartMate 3 ventricular assist type device: case report. Colombian Journal of Anesthesiology. 2020;48:40–44.

Read the Spanish version of this article at: <http://links.lww.com/RCA/A873>.

Copyright © 2019 Sociedad Colombiana de Anestesiología y Reanimación (S.C.A.R.E.). Published by Wolters Kluwer. This is an open access article under the CC BY-NC-ND license (<http://creativecommons.org/licenses/by-nc-nd/4.0/>).

Correspondence: Universidad Industrial de Santander, Facultad de Salud, Carrera 32 # 29–31, Bucaramanga, Santander, Colombia.
E-mail: lizbevi901013@hotmail.com

Colombian Journal of Anesthesiology (2020) 48:1

<http://dx.doi.org/10.1097/CJ9.0000000000000117>

Objetivo: describir el uso del bloqueo del plano del músculo erector de la espina (ESP) como técnica analgésica de rescate en un paciente llevado a implante de DAV tipo HeartMate 3.

Métodos: reporte de caso y revisión de tema.

Resultados: se presenta el caso de un paciente con cardiopatía isquémica y disfunción ventricular severa, que fue llevado a un implante de DAV tipo HeartMate 3 como terapia destino, bajo anestesia general y protocolo de analgesia postoperatoria con fentanil y acetaminofén. Durante el posoperatorio presentó dolor agudo de intensidad severa (Escala Visual Análoga: 8-10/10), por lo que se aplicó una técnica regional de rescate: bloqueo ESP, la cual mostró resultados satisfactorios con control analgésico óptimo (Escala Visual Análoga: 1-3/10).

Conclusiones: el bloqueo ESP fue una opción segura y efectiva como parte de una estrategia analgésica postoperatoria para un paciente con implante de un DAV tipo HeartMate 3.

Introduction

Heart failure is a growing healthcare problem worldwide, despite all the progress made in terms of pharmacological therapy.^{1,2} There is a particular group of patients with severe heart dysfunction that develop refractory symptoms to conventional medical therapy, which is associated with poor quality of life and high mortality rates.^{2,3}

In response to the limited number of pharmacological options in this clinical setting, the use of ventricular assist devices (VAD) as destination therapy has been implemented in the last few years in patients with advanced cardiac failure; this strategy has proven to be effective, and provides adequate quality of life which makes it increasingly popular around the world.^{4,5}

During the perioperative period, one of the challenges of anesthetic management in patients undergoing The HeartMate 3 (Abbott, Chicago, IL, USA) type VAD implantation in postoperative pain control, an issue that becomes relevant in view of the type of surgical approach, the manipulation of intrathoracic organs, and the use of thoracotomies, which are all factors that may increase the occurrence of cardiopulmonary complications and hospital length of stay.⁶⁻⁸

Currently, the recommendation is to use multimodal analgesia, including regional techniques such as epidural analgesia or paravertebral block; however, the above-mentioned techniques may be limited by the use of anticoagulants during the perioperative period.⁵⁻⁸

Recently, Forero et al⁹ described the erector spinae plane (ESP) block as an effective approach to neuropathic pain of the chest wall and analgesia after thoracic surgery. This case report discusses the use of this rescue analgesia technique for the management of acute postoperative pain in a patient undergoing HeartMate 3 type VAD implantation.

Clinical case

Male, 74-year old patient with a history of chronic kidney disease stage 3, ischemic cardiomyopathy with left

ventricular ejection fraction of 20%, and coronary heart disease with angioplasty plus stents, INTERMACS 4 (Interagency Registry for Mechanically Assisted Circulatory Support). The patient was managed by the heart failure team with levosimendan boluses and recurrent hospitalizations. Body weight: 65 kg; size: 1.63 m.

The patient received a HeartMate 3 type VAD implant as destination therapy; the surgical approach was sternotomy under balanced general anesthesia. The induction of anesthesia was with lidocaine, fentanyl, propofol, and vecuronium, and orotracheal intubation through direct laryngoscopy. The maintenance of anesthesia was performed with fentanyl, propofol, and sevoflurane infusion. A PCA (Patient Controlled Analgesia) regimen with bolus doses of fentanyl 20 µg, 5-minute block interval, maximum dose of 200 µg in 4 hours and oral acetaminophen 500 mg every 6 hours was established.

During the first 48 hours after surgery, the patient experienced very severe pain—visual analogue scale (VAS) 8 to 10, predominantly in the left hemithorax, which was partially modulated with the PCA system and recorded a use of 540 µg of fentanyl in 48 hours (Table 1). In addition, a left lung atelectasis was documented and interpreted by the treating physician as a complication secondary to the shallow breathing pattern caused by pain. Simultaneously, the patient presented with nausea, vomiting, and hallucinations, that were considered adverse effects from the use of opioids. Consequently, 3 days after surgery, the decision was made to perform a rescue ESP block with interfascial catheter implant.

Since the patient was anticoagulated with unfractionated heparin infusion, the infusion was discontinued 4 hours before the procedure. The patient was transferred to the operating room after submitting the informed consent, and the ESP block was performed under ultrasound guidance, in accordance with the technique described by Forero et al⁹ with a single Tuohy No. 18 needle puncture in the left hemithorax, at T6 to T7; 0.25% bupivacaine with epinephrine, 0.5% lidocaine, and 4 mg of dexamethasone were administered, for a total volume of 20 mL. The interfascial catheter was inserted without any complications (Fig. 1). At the end of the procedure, the pain intensity dropped to mild (VAS: 1-3) and the anticoagulation was reinstated 2 hours after the procedure.

Table 1. Fentanyl patient controlled analgesia opioid use log.

	Before the block		After the block		
	Day 1	Day 2	Day 3	Day 4	Day 5
Visual Analogue Scale	9-10/10	8/10	3/10	1/10	1/10
Total dose used (µg)	340	200	60	20	0

VAS=visual analogue scale.

Source: Authors.

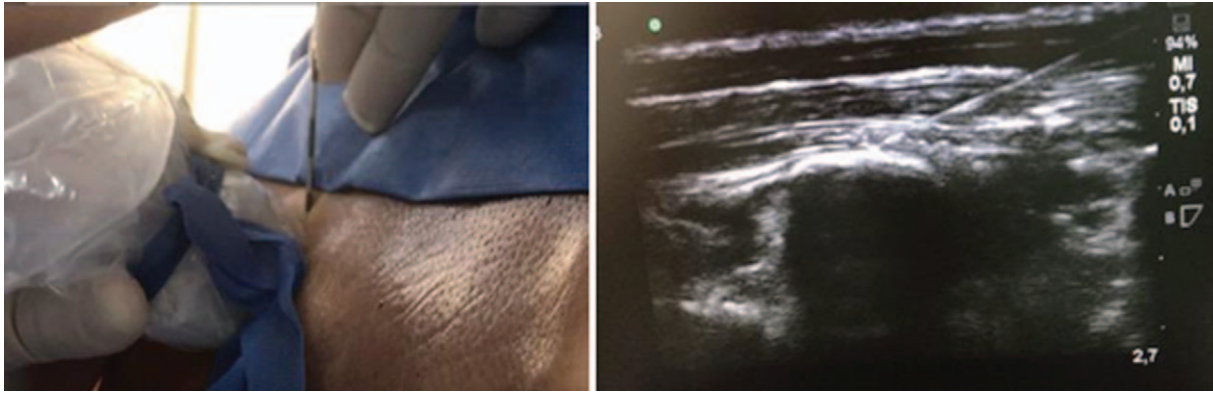


Figure 1. In-plane T6 to T7 puncture.
Source: Authors.

Follow-up: 1 rescue bolus with 0.25% bupivacaine 20 mL every 24 hours for 3 days through the catheter were required. Analgesia control VAS: 1 to 3 and reduced use of fentanyl at 80 μ g at 96 hours, without any further adverse effects (Table 1). The decision was made to remove the catheter 5-days postimplantation, together with the thoracotomy tubes, and discontinuation of heparin for 4 hours. There were no complications.

Discussion

Long-term VADs as destination therapy or as bridge therapy to recovery are increasingly being used for the management of patients with refractory heart failure.²⁻⁵ Currently, one of the challenges in perioperative management is adequate control of analgesia. This is because the surgical technique involves sternotomy or thoracotomy,^{5,10} and in the particular case of the HeartMate 3 (Abbott, Chicago, IL, USA) device, its intrapericardial localization at the level of the left ventricular apex in patients with cardiomegaly, positions the device against the rib cage^{5,10} (Fig 2), which simultaneously increases the pain intensity from moderate to severe and in some cases may lead to difficult pain management, with a higher incidence of pulmonary complications due to the shallow breathing pattern, hypoventilation, and inability to produce effective coughing, which promotes the development of atelectasis and pneumonia, with increased morbidity and mortality.¹¹ In addition, when oxygenation and ventilation are compromised, increased pulmonary vascular resistance is encouraged, which may have a negative impact on the right ventricular function,¹² hence disrupting the hemodynamic performance and the patient's evolution, resulting in extended hospitalization.

In our institution, the management of analgesia for heart surgery patients is done using the intravenous fentanyl PCA system and oral acetaminophen. However, the management of acute postoperative pain in HeartMate 3 patients has been challenging in terms of analgesia control because occasionally it may require rescue boluses

with other morphine-like opioids, increasing the probability of adverse effects.

Consequently, the decision was made to look for a rescue alternative to help us achieve adequate pain

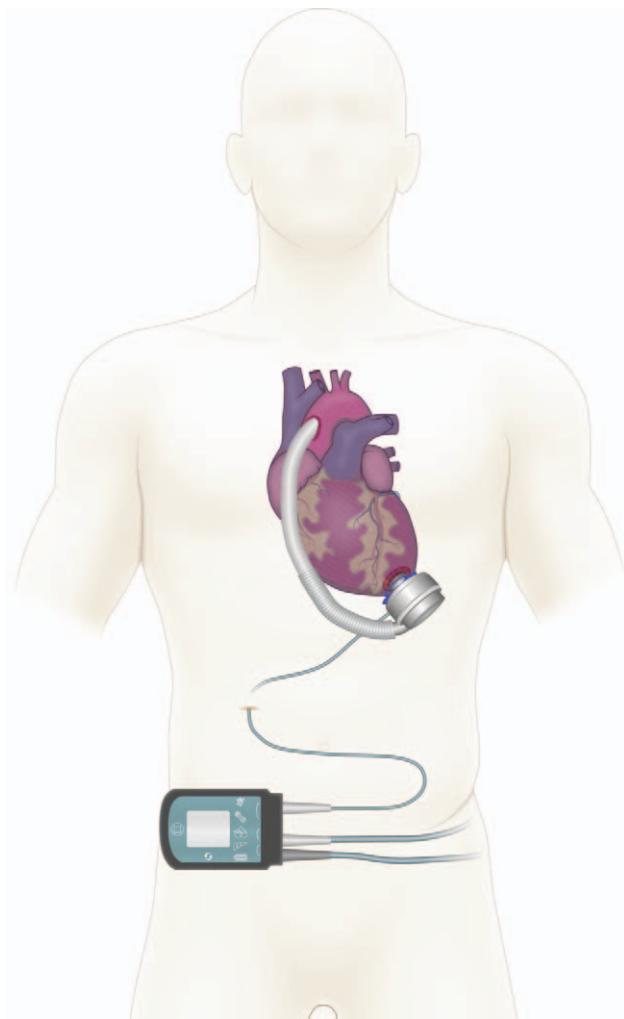


Figure 2. HeartMate 3 ventricular assist devices schematic representation.
Source: Authors.

control and allow satisfactory cardiopulmonary rehabilitation. The ESP block was then an interesting option.

The ESP block at the thoracic level was initially described by Forero et al⁹ as a regional technique for peripheral block at the interfascial level, administering a certain volume of local anesthetic agent into a deep place of the erector spinae muscle. The anesthetic agent spreads longitudinally at the cephalic-caudal and ventral-dorsal level, impregnating the ventral and dorsal branches of the spinal root nerves in the thoracic region, extending 3 to 5 dermatomes at the upper and lower levels of the puncture site, according to the findings of the anatomical dissection in cadaveric models and confirmed with radiological studies.¹³

In addition, there is impregnation of the local anesthetic agent at the level of the thoracic sympathetic chain, which blocks the autonomic response and enhances visceral pain control.⁹ It must be highlighted that due to its easy identification with ultrasound, the puncture site, and the distribution of the anesthetic agent at the interfascial level, this represents a safe technique for the management of somatic and visceral pain. Nevertheless, there needs to be awareness of the fact that it only produced ipsilateral block at the puncture site and hence 2 punctures will be needed to achieve a complete approach in surgical procedures with central sternotomy-like incisions.

Since the technique was first described in 2016, multiple papers have been published in the literature on the analgesic use of the ESP block for rib fractures,¹⁴ non-cardiac thoracic surgery^{9,15} and breast surgery.^{16,17} In heart surgery, the information is limited; some successful cases have been described for thoracic approaches¹⁰ and in minimally invasive surgery.¹⁸ Recently, the use of the ESP block was reported in patients undergoing left VAD implantation through thoracotomy, using continuous infusion of local anesthetic for analgesia control purposes, with optimal results.¹⁰ In this particular case, maintenance was provided with intermittent boluses (daily), but when comparing the results, similar behaviors may be observed with regards to pain perception and the use of opioids.

Conclusion

The US-guided ESP block at the thoracic level was an innovative, easy, and safe regional technique, which provided an effective postoperative management option as part of the multimodal analgesia strategy in a patient undergoing HeartMate 3 type VAD implantation.

Patient opinion

The patient said to have experienced considerable improvement and comfort after the procedure. After doing a risk-benefit analysis, the patient stated that he would

highly recommend the procedure and agree to undergo the procedure again.

Ethical considerations

Protection of persons and animals. The authors declare that all the procedures were conducted in accordance with the ethical standards of the responsible human experimentation committee and in accordance with the World Medical Association and the Declaration of Helsinki.

Confidentiality of the data. The authors declare that their usual workplace protocols on the disclosure of patient information were followed.

Right to privacy and informed consent. The authors have obtained the informed consent of the patient discussed in this article.

Funding

The authors did not receive any sponsorship to complete this article.

Conflicts of interest

The authors have no conflict of interest to disclose.

References

1. Mozaffarian D, Benjamin EJ, Go AS, et al. Executive summary: Heart disease and stroke statistics-2016 update: a report from the American Heart Association. *Circulation* 2016;133:447-454.
2. Sunagawa G, Koprivanac M, Karimov JH, et al. Current status of mechanical circulatory support for treatment of advanced end-stage heart failure: successes, shortcomings and needs. *Expert Rev Cardiovasc Ther* 2017;15:377-387.
3. Levy WC, Mozaffarian D, Linker DT, et al. Can the Seattle Heart Failure Model be used to risk-stratify heart failure patients for potential left ventricular assist device therapy? *J Hear Lung Transplant* 2009;28:231-236.
4. Estep JD, Trachtenberg BH, Loza LP, et al. Continuous flow left ventricular assist devices: shared care goals of monitoring and treating patients. *Methodist DeBakey Cardiovasc J* 2015;11:33-44.
5. Figueredo A, Salazar L, Echeverría LE, et al. Reporte del primer caso de implante exitoso de asistencia ventricular izquierda HeartMate II como terapia de destino en Suramérica. *Rev Colomb Cardiol* 2016;23:552.
6. Rafiq S, Steinbrüchel DA, Wanscher MJ, et al. Multimodal analgesia versus traditional opiate based analgesia after cardiac surgery, a randomized controlled trial. *J Cardiothorac Surg* 2014;9:52.
7. Mehta Y, Arora D. Benefits and risks of epidural analgesia in cardiac surgery. *J Cardiothorac Vasc Anesth* 2014;28:1069-1075.
8. Bignami E, Castella A, Pota V, et al. Perioperative pain management in cardiac surgery: a systematic review. *Minerva Anesthesiol* 2018;84:488-503.
9. Forero M, Adhikary SD, Lopez H, et al. The erector spinae plane block: a novel analgesic technique in thoracic neuropathic pain. *Reg Anesth Pain Med* 2016;41:621-627.
10. Adhikary SD, Prasad A, Soleimani B, et al. Continuous erector spinae plane block as an effective analgesic option in anticoagulated patients after left ventricular assist device implantation: a case series. *J Cardiothorac Vasc Anesth* 2019;33:1063-1067.
11. Moliner Velázquez S, Rubio Haro R, De Andrés Serrano C, et al. Regional analgesia in postsurgical critically ill patients. *Rev Esp Anestesiol Reanim* 2017;64:144-156.

12. Sen A, Larson JS, Kashani KB, et al. Mechanical circulatory assist devices: a primer for critical care and emergency physicians. *Crit Care* 2016;20:1–20.
13. Adhikary SD, Bernard S, Lopez H, et al. Erector spinae plane block versus retrolaminar block. *Reg Anesth Pain Med* 2018;43:1.
14. Hamilton DL, Manickam B. Erector spinae plane block for pain relief in rib fractures. *Br J Anaesth* 2017;118:474–475.
15. Forero M, Rajarathinam M, Adhikary S, et al. Continuous erector spinae plane block for rescue analgesia in thoracotomy after epidural failure: a case report. *A A Case Rep* 2017;8:254–256.
16. Bonvicini D, Tagliapietra L, Giacomazzi A, et al. Bilateral ultrasound-guided erector spinae plane blocks in breast cancer and reconstruction surgery. *J Clin Anesth* 2018;44:3–4.
17. Orozco E, Serrano RE, Rueda-Rojas V, et al. Erector spinae plane (ESP) block for postoperative analgesia in total radical mastectomy: case report. *Colombian Journal of Anesthesiology* 2018;46 (suppl 1): 66–68.
18. Leyva FM, Mendiola WE, Bonilla AJ, et al. Continuous erector spinae plane (ESP) block for postoperative analgesia after minimally invasive mitral valve surgery. *J Cardiothorac Vasc Anesth* 2018;32:2271–2274.