



# Colombian Journal of Anesthesiology

*Revista Colombiana de Anestesiología*

[www.revcolanest.com.co](http://www.revcolanest.com.co)

OPEN

 Wolters Kluwer

IMAGES

## The usefulness of the videolaryngoscope for the diagnosis of an unknown epiglottic tumor

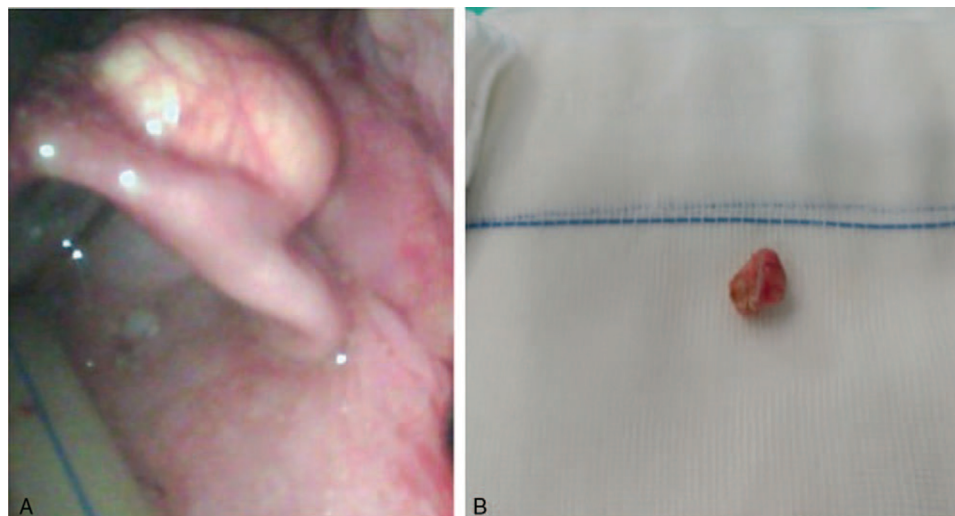
### Utilidad del videolaringoscopio en el diagnóstico de un tumor de epiglotis no conocido

Mercedes Benítez-Jiménez, María Ángeles Rodríguez-Navarro, Petra González-Pérez, Clara Díaz-Alejo, Ana Belén Alcaraz-Martínez, Lorenzo Sánchez-Ródenas

Anesthesia and Pain Department, Hospital General Universitario J.M. Morales Meseguer, Murcia, Spain.

**Keywords:** Airway Management, Laryngoscopy, Epiglottis, Laryngeal Neoplasms, Intubation

**Palabras clave:** Manejo de la vía aérea, Laringoscopia, Epiglotis, Neoplasias Laríngeas, Intubación



**Figure 1. (A) Epiglottic mass seen through the video-laryngoscope. (B) Epiglottic mass following the surgical resection.**  
Source: Authors.

How to cite this article: Benítez-Jiménez M, Rodríguez-Navarro MA, González-Pérez P, Díaz-Alejo C, Alcaraz-Martínez AB, Sánchez-Ródenas L. The usefulness of the videolaryngoscope for the diagnosis of an unknown epiglottic tumor. Colombian Journal of Anesthesiology. 2019;47:69-70.

Read the Spanish version of this article at: <http://links.lww.com/RCA/A836>.

Copyright © 2018 Sociedad Colombiana de Anestesiología y Reanimación (S.C.A.R.E.). Published by Wolters Kluwer. This is an open access article under the CC BY-NC-ND license (<http://creativecommons.org/licenses/by-nc-nd/4.0/>).

Correspondence: Anesthesia and Pain Department, Hospital General Universitario J.M. Morales Meseguer, Calle Marqués de los Vélez, Murcia 30009, Spain. E-mail: [Marodrigueznavarro@yahoo.es](mailto:Marodrigueznavarro@yahoo.es)

Colombian Journal of Anesthesiology (2019) 47:1

<http://dx.doi.org/10.1097/CJ9.0000000000000089>

The contribution of video-laryngoscopy to improving the process of orotracheal intubation has been shown in various publications emphasizing an improved and better quality vision of the mouth and the larynx; it is extremely valuable for teaching purposes and is part of the algorithm for the intubation of a predicted difficult airway.<sup>1,2</sup>

This article discusses the case of a 54-year-old patient admitted to the emergency OR for surgery of an ascending colon neoplasm and secondary intestinal obstruction. The patient has a history of smoking 10 packs/year, criteria consistent with chronic bronchial disease, and hepatitis C.

In the light of the risk of bronchoaspiration, induction, and rapid sequence intubation were conducted uneventfully. During the laryngoscopy with a Macintosh, an epiglottic mass was identified. Following the intubation and the tracheal pneumo-tamponade, we conducted a second laryngoscopy using a video laryngoscope Glidescope Titanium (Verathon Medical Bothell, WA, USA), which clearly revealed an epiglottic tumor.

After obtaining the consent of a family member, the planned hemicolectomy was conducted, in addition to a resection through laryngeal microsurgery and a biopsy of the epiglottic tumor identified (0.75 cm) (Fig. 1A and B).

Several papers argue that the total time elapsed during intubation and isolation of the airway is longer with the use of the video-laryngoscope versus the routine laryngoscopy, when the operator is still in the learning curve<sup>2</sup>; this is why the laryngoscope was used.

The use of video-laryngoscopes—Glidescope, King Vision—initially designed to facilitate orotracheal intubation, is very frequent in the algorithm for managing a difficult airway,<sup>3</sup> in addition to a very exciting application in oropharyngeal surgery.<sup>4</sup> Furthermore, we find that the device allows for an easy and minimally invasive exploration as compared against laryngoscopy using a rigid laryngoscope, as illustrated in our case in which the

problem was solved in the same surgical-anesthetic procedure.

## Ethical disclosures

**Protection of persons and animals:** The authors claim that no experiments in humans or animals were conducted for this research.

**Confidentiality of the information:** The authors declare that they followed the protocols of their workplace with regard to disclosure of patient data.

**Right to privacy and informed consent:** The authors declare that this article does not disclose any patient information.

## Funding

Author's own resources.

## Conflicts of interest

Authors declare no conflicts of interest implied in the writing of this manuscript.

## References

1. Griesdale DE, Liu D, McKinney J, et al. Glidescope® video-laryngoscopy versus direct laryngoscopy for endotracheal intubation: a systematic review and meta-analysis. *Can J Anaesth* 2012;59:41–52.
2. Lewis SR, Butler AR, Parker J, et al. Videolaryngoscopy versus direct laryngoscopy for adult patients requiring tracheal intubation. *Cochrane Database Syst Rev* 2016;11:CD011136.
3. España Fuente L, De la Rica Fernández P, González González JL. Use of King Vision® videolaryngoscope in an unanticipated difficult airway in an adult patient with giant vallecular cyst, a case report. *Rev Esp Reanim* 2017;64:61–67.
4. Bruno E, Dauri M, Mauramati S, et al. Utility of glidescope videolaryngoscopy in surgical procedures involving the larynx. *Acta Otorhinolaryngol Ital* 2015;35:45–48.