



# Colombian Journal of Anesthesiology

## Revista Colombiana de Anestesiología

www.revcolanest.com.co



### Case report

## The Bougie or “Tactile Stylet”, a useful classic alternative in modern intubation. Regarding a clinical case in the Hospital Universitario Nacional de Colombia<sup>☆</sup>



José Ricardo Navarro-Vargas<sup>a,b,c,e,\*</sup>, Rayssa Minella Becerra-Orjuela<sup>a,b,c</sup>,  
Mario Alberto Gutiérrez-León<sup>d,e</sup>

<sup>a</sup> Hospital Universitario Nacional de Colombia, Universidad Nacional de Colombia, Bogotá D.C., Colombia

<sup>b</sup> Universidad Nacional de Colombia, Faculty of Medicine, Bogotá D.C., Colombia

<sup>c</sup> Specialized Anesthesiology Unit, Surgery Department, School of Medicine, Universidad Nacional de Colombia, Bogotá D.C., Colombia

<sup>d</sup> Clínica del Country, Bogotá D.C., Colombia

<sup>e</sup> Clínica Piloto, Profamilia, Bogotá D.C., Colombia

### ARTICLE INFO

#### Article history:

Received 9 December 2016

Accepted 4 May 2017

Available online 27 June 2017

#### Keywords:

Airway management

Intubation

Intubation, methods

Intubation, intratracheal

Anesthesia

### ABSTRACT

**Introduction:** The gum elastic bougie or Eschmann stylet is a tool designed to guide intratracheal intubation that is underutilised in our setting, despite scientific information confirming that it is highly useful in difficult intubation. This case report describes the clinical use of a simple and practical device that is seldom used on our setting, especially in patients with difficult airways.

**Clinical findings:** The case presented is that of a 63-year-old female patient with a history of rheumatoid arthritis and diagnosed with abscesses in the elbow and gluteal region requiring surgical drainage. After the induction of general anesthesia, when laryngoscopy with a conventional laryngoscope was attempted, it was impossible to visualise any of the laryngeal structure (Cormack IV). With the help of the bougie, tracheal intubation was possible on first attempt.

**Treatment:** The bougie is a highly useful tool in cases of difficult intubation in anesthesiology services and intensive or emergency care units. However, its use is still not widespread in our setting.

**Conclusion:** The bougie or “tactile stylet” is a low-cost, easy-to-use device that is useful as a first choice in the management of anticipated and unanticipated difficult airways.

© 2017 Sociedad Colombiana de Anestesiología y Reanimación. Published by Elsevier España, S.L.U. This is an open access article under the CC BY-NC-ND license (<http://creativecommons.org/licenses/by-nc-nd/4.0/>).

<sup>☆</sup> Please cite this article as: Navarro-Vargas JR, Becerra-Orjuela RM, Gutiérrez-León M. El Bougie o “Estilete Tactil”, una alternativa clásica útil en la intubación moderna. A propósito de un caso clínico en el Hospital Universitario Nacional de Colombia. Rev Colomb Anestesiología. 2017;45:262-266.

\* Corresponding author at: Facultad de Medicina, Universidad Nacional de Colombia, Ciudad Universitaria, Bogotá, Colombia.

E-mail address: [jrnavarro@unal.edu.co](mailto:jrnavarro@unal.edu.co) (J.R. Navarro-Vargas).

2256-2087/© 2017 Sociedad Colombiana de Anestesiología y Reanimación. Published by Elsevier España, S.L.U. This is an open access article under the CC BY-NC-ND license (<http://creativecommons.org/licenses/by-nc-nd/4.0/>).

## El Bougie o “Estilete Tactil”, una alternativa clásica útil en la intubación moderna. A propósito de un caso clínico en el Hospital Universitario Nacional de Colombia

### R E S U M E N

#### Palabras clave:

Manejo de la vía aérea  
Intubación  
Intubación, métodos  
Intubación intratraqueal  
Anestesia

**Introducción:** El gum elastic bougie o estilete de Eschmann es una herramienta diseñada para guiar la intubación endotraqueal, subutilizada en nuestro medio a pesar de la información científica que sustenta su gran utilidad en casos de intubación difícil. Este reporte de caso describe el uso clínico de un dispositivo sencillo y práctico, poco utilizado en nuestro medio, especialmente en pacientes que presentan una vía aérea difícil.

**Hallazgos clínicos:** Se presenta el caso de una paciente de 63 años con antecedente de artritis reumatoidea y diagnóstico de abscesos en codo y región glútea, quien requirió drenaje quirúrgico. Luego de la inducción de la anestesia general, al intentar practicar la laringoscopia con laringoscopio convencional, no fue posible visualizar ninguna estructura laríngea (Cormack IV). Con la ayuda del bougie se logró practicar la intubación traqueal al primer intento.

**Tratamiento:** El bougie es una herramienta de gran utilidad en casos de intubación difícil, en servicios de anestesiología, cuidados intensivos o urgencias, pero su uso aun no se ha generalizado en nuestro medio.

**Conclusión:** El bougie o estilete tactil es un dispositivo económico, de fácil manejo y útil como primera elección en el manejo de la vía aérea difícil anticipada y no anticipada.

© 2017 Sociedad Colombiana de Anestesiología y Reanimación. Publicado por Elsevier España, S.L.U. Este es un artículo Open Access bajo la licencia CC BY-NC-ND (<http://creativecommons.org/licenses/by-nc-nd/4.0/>).

### Clinical case description

63-Year-old female patient, 49 kg with an history of rheumatoid arthritis and osteoporosis, receiving multiple disease-modifying treatments, corticoids and biological medications. During a follow-up visit in rheumatology, a radiography of the cervical spine revealed evidence of subluxation of C1-C2 and C2-C3. **Fig. 1** The patient presented with a clinical picture of chronic osteomyelitis of the elbows and pelvis that required a surgical procedure consisting of surgical cleaning and debridement of the left elbow and drainage of the gluteal abscess.

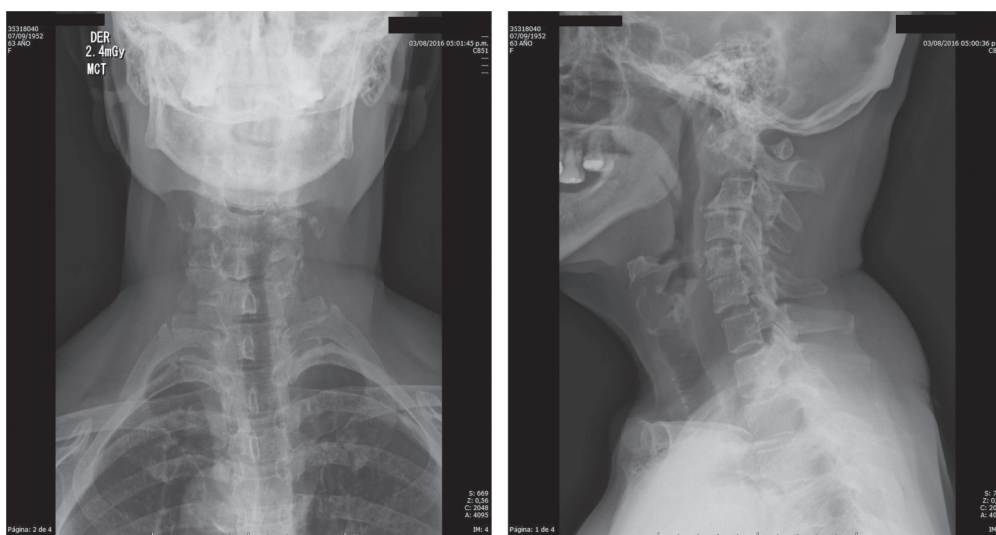
Significant findings during the pre-anesthetic assessment included limited oral opening (2.5 cm), a thyromental distance of 5 cm, severe limitation of cervical extension, and two unstable dental structures. The patient was haemodynamically stable upon arriving at the operating room, with BP 125/85 mm Hg, HR 78 bpm, BR 14, SpO<sub>2</sub> 95% FiO<sub>2</sub> 0.21. After confirmation of pre-operative fasting, signed informed consent, and non-invasive monitoring, induction was initiated with 70 mg IV of propofol, 100 mg IV of fentanyl, and 2.5 mg IV of rocuronium followed by 100 mg IV of succinylcholine. Laryngoscopy was performed with great difficulty due to the limited oral opening and without next extension. Given that laryngeal structures could not visualised (Cormack IV) the decision was made to insert a bougie while moving and holding the oropharyngeal structures forward with the laryngoscope. The angulated flexible tip was slid upward until the contact of the device with the carina could be felt after it had advanced approximately 25 cm. There was no tactile sensation of the tracheal cartilage. Next, a No. 7 tracheal tube was inserted through the device, and the bougie was removed. The patient was connec-

ted to an anesthesia machine, uniform pulmonary ventilation was assured, and the tracheal tube was connected. Ventilation parameters were adjusted, and balanced general anesthesia was administered. The patient was in prone position during the surgical procedure. Awake extubation was performed, and there were no complications. During the immediate post-operative period, the patient did not report pharyngeal pain, dysphonia or pharyngeal bleeding.

### Discussion

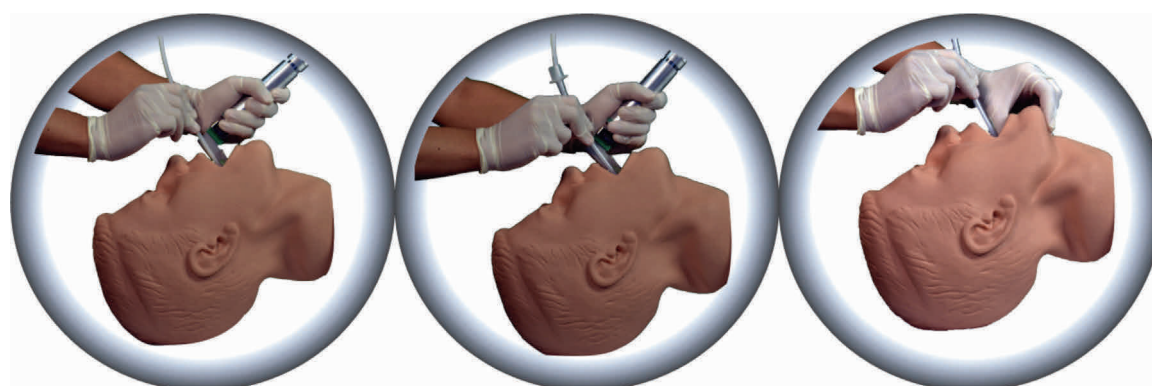
The gum elastic bougie (GEB), or Eschmann endotracheal introducer, is a rescue device used for rescues in cases of difficult airway, especially anticipated ones.<sup>1</sup> It is important in operating rooms as a tool for the anaesthetist, and in emergency departments, where it has proven to be of vital importance. Despite its name, the GEB is neither made of gum, nor is it elastic, or a bougie for tracheal dilatation. For this reason, the authors believe that the term that best describes its features is that of “Tactile stylet”: when taken between the right index finger and thumb, it provides tactile sensation of the tracheal cartilages, and when advanced beyond 20 cm, the distal end touches the carina, as was previously described (**Fig. 2**).<sup>2-4</sup>

The incorporation of the bougie into anesthesiology was thanks to Sir Robert Macintosh (1949), who is credited with using it as a guide for tracheal intubation. Duckworth gave it the name of stylet, and Paul Venn (1973) introduced it in clinical practice. The latter worked as an anesthesiology consultant for Eschmann Brothers & Walsh Ltd., and introduced the following modifications: a 35° curve in the distal end, a



**Fig. 1 – Radiography of the cervical spine.**

Source: Authors.



Phase I. Laryngoscopy is performed and the bougie is inserted with the end bent toward the glottis.

Phase II. The tube is slid freely through the bougie with the laryngoscope in situ (some prefer to hold the laryngoscope to make way for the tube).

Phase II. The tube is slid freely through the bougie without the laryngoscope (some prefer to remove the laryngoscope to protect the teeth).

**Fig. 2 – Passage of the bougie and the tracheal tube.**

Source: Authors.

length of 60 cm, a diameter of 5 mm, and two-layer construction — an internal polyester layer and the outer resin lining. This made it rigid (semi-rigidity) but also flexible so that it could work as a true introducer in the trachea with minimal risk of damaging soft tissues.<sup>5,6</sup>

In 2014, in an editorial of the *Anaesthesia* journal entitled “The humble bougie... forty years and still counting?”,<sup>7</sup> Rai reports that the device is more widely used in the United Kingdom for difficult intubation conditions and is available in more than 90% of difficult airway carts. The bougie is a priority resource in the “Plan A” of the Difficult Airway Society’s (DAS) Guidelines for the management of unanticipated difficult intubation.<sup>8</sup>

Several studies and algorithm reviews from Australia, the United States of America, Singapore and France regarding the

management of difficult airways and intubation describe the bougie as the most commonly used, most useful and most effective device for difficult airway management.<sup>9-12</sup>

Reports about bougie use, even by non-anaesthetists, show high success rates, ranging from 89% on the first attempt to 94%–100% in the second attempt.<sup>13,14</sup> Complications are rare and have been mostly associated with the incorrect use of the device.<sup>15,16</sup> The bougie has also been incorporated into video laryngoscopes, as is the case of the CoPilot VL, that has a port through which the bougie is passed to facilitate tracheal intubation.<sup>17</sup>

The Latin American experience with this device is minimal in comparison with its use in Europe and especially in the United Kingdom, not only in patients with a difficult airway (when the vocal cords cannot be visualised, Cormack III–IV)

but also because of the reported reduction in the incidence of failed intubation and cricothyroidotomy.<sup>18–20</sup> It is striking noting that in more developed countries, such as the United Kingdom, bougie use is so wide-spread among anaesthetists, and paradoxically, it is only seldom used in countries with low economic resources where great efforts go into the acquisition of much more costly equipment and technologies that require more training and are not always effective.

### Insertion technique

The technique is very simple. It consists of advancing the device through the trachea so that the tracheal tube can be then be inserted through it, similar to the Seldinger technique used for other cannulations.<sup>2</sup> The process consists two phases. First, the bougie is slid posterior to the epiglottis, with the distal end bent forward.<sup>21</sup> The device must be held between the right index finger and thumb so that the movement across the tracheal rings or, failing this, contact with the carina or the bronchi can be felt. To facilitate the second phase, which is where most obstacles occur, some recommend rotating the orotracheal tube 90 degrees counter-clockwise, keeping the tube bevel pointing backward.<sup>22,23</sup> There is controversy about maintaining the laryngoscope in place to mobilise the oropharyngeal structures forward while the tracheal tube is inserted since it has been reported that this hinders the sliding of the tube (Fig. 2).<sup>24,25</sup>

### Recommendations

Of crucial importance are the recommendations of never forcing the bougie and, it being a “Tactile stylet”, to pay attention to the “clicks” caused by the end of the device hitting the tracheal rings, the feeling of standstill when it reaches the carina or even a small bronchus (at approximately 40 cm), and, finally, the coughing (the least perceptible of the three) that can occur in some patients without muscle relaxation. When the patient is not adequately induced (semi-unconscious) there may be a risk of bronchospasm when the tip of the bougie hits the carina. That said, when it moves toward the esophagus, where the mucous membrane is smooth, it does not hit any structure and can advance the whole length of it, beyond 45 cm.<sup>3,26</sup>

Regarding the above, it has been empirically observed in the population of patients undergoing surgery at the National University Hospital of Colombia (Hospital Universitario Nacional de Colombia), that the “tactile stylet” can also be useful as a first approach during a Cormack II or IV laryngoscopy without producing adverse effects in the patient or prolonging the process of securing the airway, just as was demonstrated in this case. Additional studies are required to evaluate the efficacy of bougie use compared to other supraglottal devices in terms of the success of orotracheal intubation and the time required to complete it.

### Conclusion

Although the incidence of difficult airway is relatively low,<sup>27</sup> the bougie has been shown to be a useful, effective, low-cost and very easy-to-use device for facilitating intubation

when the vocal cords cannot be completely visualised. Given the medical implications and the serious consequences when faced with a patient with a difficult airway, this article proposes reflecting on rescuing the use of the bougie and making it available in airway carts so that it may become the first choice for the management of anticipated and unanticipated difficult airways.

### Ethical disclosures

**Protection of human and animal subjects.** The authors declare that no experiments were performed on humans or animals for this investigation.

**Confidentiality of data.** The authors declare that no patient data appears in this article.

**Right to privacy and informed consent.** The authors declare that no patient data appears in this article.

### Funding

Authors' own resources.

### Conflict of interest

Authors declare that there is no conflict of interest.

### Acknowledgement

The authors thank Jorge Humberto Reyes Pimiento, industrial designer, for the creation of Fig. 2.

### REFERENCES

1. Macintosh RR. An aid to oral intubation. *Br Med J*. 1949;1:28.
2. Kidd JF, Dyson A, Latto IP. Successful difficult intubation. Use of the gum elastic bougie. *Anaesthesia*. 1988;43:437–8.
3. Henderson JJ. Development of the gum elastic bougie. *Anaesthesia*. 2003;58:103–4.
4. El-Orbany MI, Salem MR, Joseph NJ. The Eschmann tracheal tube introducer is not gum, elastic or a bougie. *Anesthesiology*. 2004;101:1240.
5. McCarroll SM, Lamont BJ, Buckland MR, Yates AP. The gum-elastic bougie: old but still useful. *Anesthesiology*. 1988;68:643–4.
6. Venn PH. The gum elastic bougie. *Anaesthesia*. 1993;48:274–5.
7. Ray MR. Editorial. The humble bougie... forty years and still counting? *Anesthesia*. 2014;69:199–203.
8. Henderson JJ, Popat MT, Latto IP, Pearce AC. Difficult Airway Society guidelines for management of the unanticipated difficult intubation. *Anaesthesia*. 2004;59:675–94.
9. Brazil V, Grobler C, Greenslade J, Burke J. Comparison of intubation performance by junior emergency department doctors using gum elastic bougie versus stylet reinforced endotracheal tube insertion techniques. *Emerg Med Australasia*. 2012;24:194–200.
10. Niven AS, Doerschug KC. Techniques for the difficult airway. *Curr Opin Crit Care*. 2013;19:9–15.



11. Koay CK. Difficult tracheal intubation analysis and management in 37 cases. *Singapore Med J.* 1998;39:112-4.
12. Detave M, Shiniara M, Leborgne JM. Use of Eschmanns gum elastic bougie in difficult orotracheal intubation, an audit over eight years of clinical practice. *Ann Fr Anesth Reanim.* 2008;27:154-7.
13. Morton T, Brady S, Clancy M. Difficult airway management in English emergency departments. *Anaesthesia.* 2000;55:485-8.
14. Latto IP, Stacey M, Mecklenburgh J, Vaughan RS. Survey of the use of the gum elastic bougie in clinical practice. *Anaesthesia.* 2002;57:379-84.
15. Kadry M, Popat M. Pharyngeal wall perforation – an unusual complication of blind intubation with gum elastic bougie. *Anaesthesia.* 1999;54:404-5.
16. Jabre P, Combes X, Bertrand L, Aaron E, Auger H, Margenet A, et al. Use of gum elastic bougie for prehospital difficult intubation. *Am J Emerg Med.* 2005;23:552-5.
17. Bougie port video laryngoscope intubation. Copilot VL.com. Available from: <https://goo.gl/XiXtpD> [accessed 20.12.16].
18. Moscati R, Jehle D, Christiansen G, D'Aprix T, Radford J, Connery C, et al. Endotracheal tube introducer for failed intubations: a variant of the gum elastic bougie. *Ann Emerg Med.* 2000;36:52-6.
19. Gataure PS, Vaughan RS, Latto IP. Simulated difficult intubation. Comparison of the gum elastic bougie and the stylet. *Anaesthesia.* 1996;51:935-8.
20. Nocera A. A flexible solution for emergency intubation difficulties. *Ann Emerg Med.* 1996;27:665-7.
21. Butler KH, Clyne B. Management of the difficult airway: alternative airway techniques and adjuncts. *Emerg Med Clin North Am.* 2003;21:259-89.
22. Dogra S, Falconer R, Latto IP. Successful difficult intubation tracheal tube placement over a gum-elastic bougie. *Anaesthesia.* 1990;45:774-6.
23. Cossham PS. Difficult intubation. *Br J Anaesth.* 1985;57:239.
24. Nolan JP, Wilson ME. Orotracheal intubation in patients with potential cervical spine injuries. *Anaesthesia.* 1993;48:630-3.
25. Whitten C. The bougie: use wisely to avoid rare but serious complications. *Junio.* 2015. Available from: <https://goo.gl/4otU1t> [accessed 08.12.16].
26. Levack ID, Masson AHB. Difficult tracheal intubation. *Anaesthesia.* 1986;41:332.
27. Shah KH, Kwong BM, Hazan A, Newman DH, Wiener D. Success of the gum elastic bougie as a rescue airway in the emergency department. *J Emerg Med.* 2011;40:1-6.