

DOI: <https://doi.org/10.5554/22562087.e937>

# Clevidipine as an antihypertensive drug in three pheochromocytoma surgeries: Case series

## *Clevidipino como fármaco antihipertensivo en tres cirugías de feocromocitoma: Serie de casos*

Carol Luis-García<sup>a</sup> , Elisa Arbonés-Aran<sup>a</sup>, Carlos Eduardo Moreno-Martínez<sup>a</sup>, Lourdes Trillo-Urrutia<sup>a</sup><sup>a</sup> Department of Anaesthesiology, Hospital del Mar, Parc de Salut Mar. Barcelona, Spain.Correspondence author: Passeig Marítim de la Barceloneta, 25, 29, 08003. Barcelona, España. Email: [61307@parcdesalutmar.cat](mailto:61307@parcdesalutmar.cat)

### Abstract

#### What do we know about this problem?

Clevidipine is a calcium antagonist with rapid onset, short half-life and no residual effect. It has been reported as a successful treatment for intraoperative hypertensive crisis secondary to pheochromocytoma, but we have just found three individual cases report about it.

#### What is the contribution of this study?

In a previous case of a patient undergoing pheochromocytoma exeresis in our hospital, we started the infusion of clevidipine during the first hypertensive peak. Now we report a series of three cases in which we started the infusion of clevidipine at low doses from the beginning of the surgery, before hypertensive crisis. We believe that initiating the clevidipine early and preventively could have helped to make the hypertensive peaks less pronounced.

#### How to cite this article?

Luis-García C, Arbonés-Aran E, Moreno-Martínez CE, Trillo-Urrutia L. Clevidipine as an antihypertensive drug in three pheochromocytoma surgeries: Case series. Colombian Journal of Anesthesiology. 2020;48(4):e937.

#### Introduction

Laparoscopic adrenalectomy is the treatment of choice of pheochromocytoma. During the first surgical phase (pneumoperitoneum insufflation, tumor and veins handling), there is a risk of hypertensive crisis due to catecholamine release. After tumor excision, patients can suffer relative vasodilation and the residual effect of antihypertensive drugs, which results in arterial hypotension. For that reason, antihypertensive drugs used in the first phase should have a rapid onset of action, short half-life and no residual effect.

#### Methods

We report a series of three cases of patients with pheochromocytoma who were treated with laparoscopic adrenalectomy. They all received clevidipine infusion from the beginning of the surgery, before they had presented hypertension, to treat and try to minimize hypertensive peaks.

#### Results

In all patients, hypertensive peaks were controlled in a few minutes. After tumor resection, clevidipine infusion was stopped in all cases, and any patient required infusion of vasopressors.

#### Discussion

Clevidipine could be a first choice antihypertensive drug in pheochromocytoma surgery. Starting the infusion of clevidipine before the hypertensive peaks could help to make them less pronounced.

#### Keywords

Antihypertensive drugs; pheochromocytoma; adrenalectomy; catecholamines.

¿Qué sabemos acerca de este problema?

El clevidipino es un antagonista del calcio de rápida aparición, vida media corta y sin efecto residual. Se ha informado que es un tratamiento exitoso para la crisis hipertensiva intraoperatoria secundaria al feocromocitoma, pero acabamos de encontrar tres informes de casos individuales sobre este fármaco.

¿Qué aporta este estudio de nuevo?

En un caso anterior de un paciente sometido a exéresis de feocromocitoma en nuestro hospital, iniciamos la infusión de clevidipino durante el primer pico hipertensivo. Ahora informamos de una serie de tres casos en los que comenzamos la infusión de clevidipino en dosis bajas desde el principio de la operación, antes de la crisis hipertensiva. Creemos que iniciar el clevidipino de manera temprana y preventiva podría haber ayudado a que los picos de hipertensión fueran menos pronunciados.

Resumen

Introducción

La adrenalectomía laparoscópica es el tratamiento de elección del feocromocitoma. Durante la primera fase quirúrgica (insuflación de neumoperitoneo, manipulación del tumor y de las venas implicadas), existe el riesgo de que se desencadenen crisis hipertensivas debido a la liberación de catecolaminas. Después de la extirpación del tumor, los pacientes pueden sufrir una vasodilatación relativa y el efecto residual de los fármacos antihipertensivos usados previamente, lo que resulta en hipotensión arterial. Por esa razón, los fármacos antihipertensivos utilizados en la primera fase quirúrgica deben tener rápido inicio de acción, vida media corta y mínimo efecto residual.

Métodos

Se describe una serie de casos de tres pacientes con feocromocitoma que fueron tratados con adrenalectomía laparoscópica. Todos recibieron infusión de clevidipino desde el comienzo de la cirugía, antes de presentar hipertensión arterial, para así intentar minimizar y tratar rápidamente los posibles picos hipertensivos.

Resultados

En todos los pacientes los picos hipertensivos se controlaron en pocos minutos. Después de la resección del tumor, la infusión de clevidipino se detuvo en todos los casos y ningún paciente requirió perfusión de vasopresores.

Discusión

El clevidipino podría ser un fármaco antihipertensivo de primera elección en la cirugía de feocromocitoma. Iniciallo antes de que ocurran los picos hipertensivos podría ayudar a que sean más leves.

Palabras clave

Fármacos antihipertensivos; feocromocitoma; adrenalectomía; catecolaminas.

INTRODUCTION

Pheochromocytoma is a tumor that produces catecholamine and is located in the adrenal medulla in 80-85% of cases. It can be associated with systemic diseases such as neurofibromatosis type 1.

Patients with pheochromocytoma can suffer symptoms as palpitations, arterial hypertension (AHT), diaphoresis or headache due to a high secretion of catecholamine.

Laparoscopic adrenalectomy is the treatment of choice, except in very large tumors or unresectable malignant tumors (1-3).

During surgery, there is a great risk of catecholamine release, especially during insufflation of the pneumoperitoneum and tumor manipulation (3). Severe hypertensive crises can occur even in patients who have never had hypertension. It is recommended to do a preoperative optimization with drugs that block the effect of catecholamine: alpha blockers, calcium channel blockers or angiotensin receptor inhibitors. For patients with tachyarrhythmia, the use of calcium channel blockers or beta-blockers (previous treatment with alpha) is recommended (4).

After tumor resection, the most common complication is severe arterial hypotension, due to an increased venous

capacitance and the residual effects of hypotensive drugs used before (5). To decrease it, it is recommended to do volume expansion during and after the surgery with fluid therapy guided by hemodynamic objectives (6), and the hypotensive drug used before tumor resection must have a short half-life.

Clevidipine is an intravenous calcium antagonist that has a rapid onset of action, short duration of effect, metabolism by plasma esterase and easy dose titration (7,8). It could be a good antihypertensive agent in these surgeries, but there are just a few publications about it (8-10). The following three cases describes its application in pheochromocytoma surgery.

## METHODS: CASES REPORT

We present a series of three consecutive patients with pheochromocytoma that were treated with laparoscopic adrenalectomy in our hospital between 2017 and 2018. Patients are satisfied with the treatment received and we have obtained the signed consent of all of them to publish their clinical data.

They were a man and two women between 54 and 73 years old that were diagnosed by an increase of plasma or

urinary levels of metanephrines and the results of an image test after they had presented clinical manifestations (table 1). They all received preoperative preparation and had normal BP and HR before surgery and on their arrival at the operating room (table 1). They were operated under general anesthesia: Anesthetic induction with propofol, rocuronium and remifentanyl. Anesthetic maintenance: sevoflurane in patients 1 and 2, desflurane in patient 3, remifentanyl infusion and bolus of rocuronium in all of them. An epidural

catheter was placed for postoperative analgesia and was used since the end of the surgery in all patients. They were monitored with Vigileo (company: Edwards Lifesciences) (6).

In patients 1 and 2, the clevidipine infusion was started at low doses a few minutes after the anesthetic induction, despite the fact that they were normotensive, to try to avoid pronounced hypertensive peaks during the surgery. They had BP up to 169/77-180/70 after the clevidipine infusion was started (figure 1). Patient 2 presented a sig-

**TABLE 1.** Patients' characteristics and diagnosis. Preoperative preparation and hemodynamic parameters.

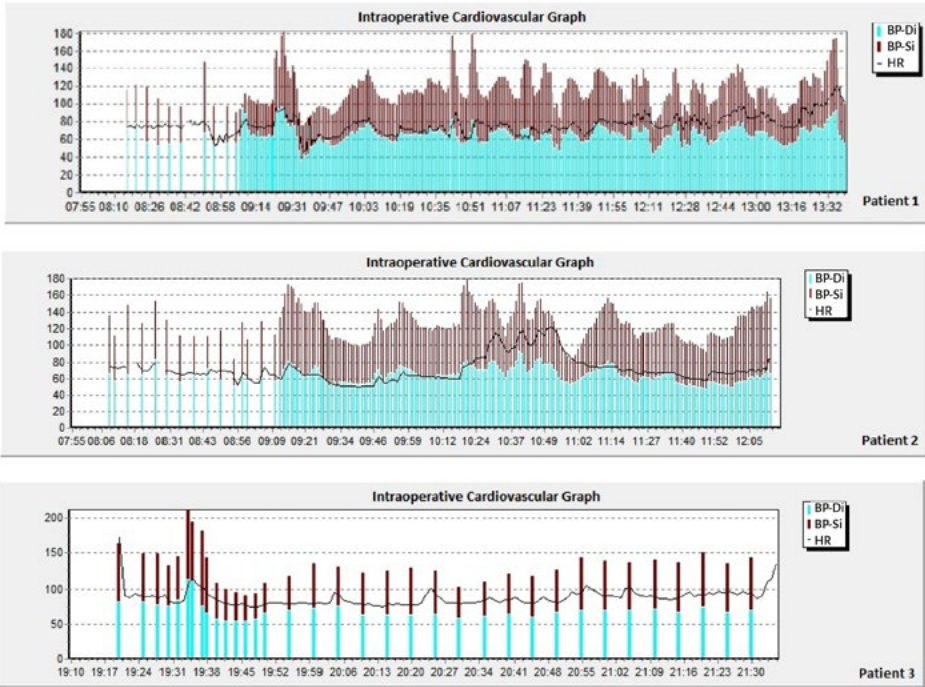
| Characteristics    | Patient 1   | Patient 2  | Patient 3   |
|--------------------|---|--|---|
| Age (years)        | 54  | 73   | 60  |
| Gender             | Female  | Male   | Female  |
| Chronic illnesses  | Diabetes, dyslipidemia, hypothyroidism, glaucoma  | Hypertension, dyslipidemia   | Ex-smoker, dyslipidemia   |
| Signs and symptoms | Recurrent hypertensive crises, tachycardia and sweating   | Hypertensive crisis with palpitations, headache, tremors, paresthesias in the extremities and coughing with hemoptysis   | Hypertensive crisis and sweating  |
| Hormonal tests     | <p><b>Metanephrines in 24h urine:</b><br/>5.210 µg/24 h<br/>(0,01-320 µg/24 h)</p> <p><b>Vanilmandelic acid in 24h urine:</b><br/>19,9 mg/24 h (0,01-6,6 mg/24 h)</p> | <p><b>Total metanephrines in plasma:</b><br/>92,7 pg/mL (0-90 pg/mL).</p> <p><b>Noradrenaline in plasma:</b><br/>3.856 pg/mL (0-420 pg/mL)</p> <p><b>Noradrenaline in 24h urine:</b><br/>1.736 nmol/d (0-97 µg/24h).</p> <p><b>Normetanephrines in plasma:</b><br/>4.424,4 pg/mL (0-196 pg/mL)</p> | <p><b>Total metanephrines in 24h urine:</b><br/>6.534 µg/24 h (0-302 µg/24 h).</p> <p><b>Normetanephrine in 24h urine:</b><br/>4.916 µg/24 h (0,01-390 µg/24 h).</p> <p><b>Noradrenaline in 24h urine:</b><br/>730 µg/24 h (0-97 µg/24 h).</p> <p><b>Adrenaline in 24h urine:</b><br/>171µg/24h 0-20 µg/24 h.</p> <p><b>Dopamine in 24h urine:</b><br/>171 µg/24 h (65-400 µg/24 h)</p> |
| Image test         | <p><b>CT:</b> Solid left adrenal 47 mm mass.</p> <p><b>Gammagraphy with 99m Tecnecio-sestamibi:</b> Suprarenal left capture</p>                                       | <p><b>CT:</b> Left suprarenal 43x31x35 mm mass</p>   | <p><b>MR:</b> Right adrenal 77x74 mm mass which is globally hyperdense with acute adrenal hemorrhage</p>  |

| Characteristics                  | Patient 1  | Patient 2            | Patient 3                                 |
|----------------------------------|--|----------------------|---|
| Pre-surgery treatment            | Doxazosine retard 8 mg/24h<br>Nifedipine retard 20mg/8h<br>Propranolol 10mg/8h | Nifedipine 20 mg/8 h | Doxazosine 4mg/24h<br>Propranolol 10mg/8h |
| Maxium BP during 48h pre surgery | 120/70 mmHg  | 135/70 mmHg          | 133/88 mmHg                               |
| Maxium HR during 48h pre surgery | 100 bpm  | 75 bpm               | 85 bpm                                    |

CT= Computed tomography, MR= Magnetic resonance.

SOURCE: Authors.

FIGURE 1. Blood pressure and heart rate during surgery.



**Patient 1:** Blood pressure peaks up to 180/70 mmHg before and during tumor resection. Punctual episodes of arterial hypotension after the tumor resection and the clamping of the veins involved.

**Patient 2:** Blood pressure peaks up to 180/70 mmHg and sinus tachycardia up to 120 beats per minute before and during tumor resection. Punctual episodes of arterial hypotension after the tumor resection and the clamping of the veins involved.

**Patient 3:** Blood pressure up to 217/107 mmHg during laryngoscopy, before starting the infusion of Clevidipine.

**BP-Di=** Diastolic blood pressure in millimeters of mercury (mmHg), **BP-Si=** Systolic blood pressure in mmHg, **HR=** Heart rate in beats per minute.

SOURCE: Authors.

nificant depression of the ST segment in derivation II of the electrocardiogram. It was in the context of hypertensive peak up to 180/70 mmHg and sinus tachycardia up to 120 beats per minute. It normalized when the tachycardia and hypertension decreased. Patient 3 presented BP up to 217/107 during laryngoscopy. In that moment, the clevidipine infusion was started and BP was controlled in three minutes and remained stable (figure 1).

After the clamping of all the veins involved, the clevidipine infusion was progressively reduced and could be removed in all of them. All patients presented episodes of arterial hypotension. In patients 1 and 2, hypotension was solved in less than 10 minutes just with fluid therapy guided by hemodynamic objectives. The hemodynamic objectives consisted of an increase of 10% or more in the cardiac index and the systolic volume index of the Vigileo monitoring system. The fluid therapy that was necessary to achieve this objectives was 1 liter of plasmalyte in patient 1 and 0.5 liters in patients 2 and 3. Patient number 3 also required a punctual 100 µg bolus of phenylephrine. They remained normotensive until the end of the surgery.

All patients were extubated in the operated room and transferred to recovery room.

Patients 1 and 3 were discharged to conventional hospital ward in six hours.

Patient 2 did not present symptoms or electrocardiogram of myocardial ischemia after surgery. Troponin curve was initially ascending, reaching a maximum of 83 ng/l. The cardiologist's diagnostic was myocardial damage in a hemodynamic context. The troponins normalized in 24h and the patient could be discharged from resuscitation area.

All of them remained with normal BP during the whole hospital admission, without the requirement of vasopressors or antihypertensive drugs. They were all discharged from hospital in less than four days.

## DISCUSSION

The second surgical period of pheochromocytoma exeresis is associated with risk of hemodynamic instability, due to manipulation of the tumor and secondary relative hypovolemia (5).

Clevidipine is an intravenous calcium antagonist with rapid onset, short half-life, minimal effect on heart rate and myocardial oxygen consumption, dose-dependent and linear effect, metabolized by plasma esterase and with easy dose titration. It does not require dose adjustment by weight, renal or hepatic function (7,8).

The risk of arterial hypotension after tumor resection is lower if the hypotensive drugs used before have a short half-life. Clevidipine has not residual hypotensive effect (7,8) after tumor resection, so the risk of hypotension might be lower.

There are just a few publications about the use of clevidipine in this type of surgeries. Its use has been reported as a successful treatment for an intraoperative hypertensive crisis secondary to an undiagnosed pheochromocytoma (9). It has been also described as a successful treatment of a patient with pheochromocytoma in the context of von Hippel Lindau disease (10).

In a previous case in our hospital, we started clevidipine infusion during the first hypertensive peak, managing to control blood pressure quickly. However, even though the hypertensive peaks lasted just a few minutes, the patient had very high BP levels momentarily, even up to 279/122 mmHg (8). In the three patients of this case series, we started the infusion of clevidipine at low doses from the beginning of the surgery, after anesthetic induction, despite the fact that they were normotensive. We believe that this could have helped to make the hypertensive peaks less pronounced (up to 180/70 mmHg after the clevidipine infusion was started). In future cases, if the patient does not present arterial hypotension, we will consider starting clevidipine infusion at low doses before the anesthetic induction, to try to minimize possible hypertensive peaks during laryngoscopy, as occurred in patient 3 that presented BP up to 217/107.

Clevidipine could be an antihypertensive agent of first choice in these interventions. We think that starting the infusion of clevidipine before the hypertensive peaks could help to make them less pronounced. However, more studies are needed to ensure its role in pheochromocytoma surgery.

## ETHICAL DISCLOSURES

### Protection of human and animal subjects.

The authors declare that no experiments were performed on humans or animals for this study.

### Confidentiality of data.

The authors declare that they have followed the protocols of their work center on the publication of patient data.

## Right to privacy and informed consent

The authors declare that no patient data appear in this article.

The authors have obtained the informed consent of the patients and/or subjects referred to in the article. This document work in the power of the correspondence author.

## ACKNOWLEDGEMENTS

### Authors' contributions

**CLG:** Interpretation of results, data analysis and writing of the manuscript.

**EAA:** Data collection, study planning.

**CEMM:** Data collection, data analysis.

**LTU:** Conception of the original project, interpretation of results and approval of the manuscript.

### Financial support and sponsorship

None.

### Conflicts of interest

None.

### Presentation of preliminary data

Euroanesthesia 2018, Copenhagen Denmark, 2-4 June, 2018.

## REFERENCES

1. Oleaga A, Goñi F. Feocromocitoma: Actualización diagnóstica y terapéutica. *Endocrinol Nutr.* 2008;55(5):202-16. DOI: [https://doi.org/10.1016/S1575-0922\(08\)70669-7](https://doi.org/10.1016/S1575-0922(08)70669-7)
2. Gardet V, Gatta B, Simonnet G, Tabarin A, Chene G, Ducassou F, Corcuff JB. Lessons from



an unpleasant surprise: a biochemical strategy for the diagnosis of pheochromocytoma. *J Hypertens*. 2001;19:1029-35.

3. Pacak K, Eisenhofer G, Ahlman H, Bornstein SR, Giménez-Roqueplo AP, Grossman AB, Kimura N, Mannelli M, McNicol AM, Tischler AS, International Symposium on Pheochromocytoma. Pheochromocytoma: recommendations for clinical practice from the First International Symposium. *N Nat Clin Pract Endocrinol Metab*. 2007;3(2):92-102. DOI: <https://doi.org/10.1038/ncpendmet0396>
4. Tauzin-Fin P, Sesay M, Gosse P, Ballanger P. Effects of perioperative alpha1 block on haemodynamic control during laparoscopic surgery for phaeochromocytoma. *Br J Anaesth*. 2004;92:512-7. DOI: <https://doi.org/10.1093/bja/aeo083>
5. Bénay CE, Tahiri M, Lee L, Theodosopoulos E, Madani A, Feldman LS, Mitmaker EJ. Selective strategy for intensive monitoring after pheochromocytoma resection. *Surgery*. 2016;159:275-83. DOI: <https://doi.org/10.1016/j.surg.2015.06.045>
6. García-Orellana M, Rivas G, Farré C, Trillo L. Monitorización hemodinámica con sistema de onda de pulso durante la cirugía del feocromocitoma. *Rev Esp Anestesiología Reanim*. 2014;61(2):116-7.
7. Deeks ED, Keating GM, Kean SJ. Clevidipine: a review of its use in the management of acute hypertension. *Am J Cardiovascular Drugs*. 2009;9(2): 117-34. DOI: <https://doi.org/10.1007/BF03256583>
8. Luis C, Arbonés E, Teixell C, Lorente L, Trillo L. Clevidipino como antihipertensivo en la cirugía de feocromocitoma. *Rev Esp Anestesiología Reanim*. 2018;65(4):225-8. DOI: <https://doi.org/10.1016/j.redar.2017.07.001>
9. Kline JP. Use of clevidipine for intraoperative hypertension caused by an undiagnosed pheochromocytoma: A case report. *AANA J*. 2010;78:288-90.
10. Bettsworth JC, Martin DP, Tobias JD. Intraoperative use of clevidipine in a patient with von Hippel-Lindau disease with associated pheoch. *J Cardiothorac Vasc Anesth*. 2013;27:749-51. DOI: <https://doi.org/10.1053/j.jvca.2011.12.005>