



DOI: <https://doi.org/10.5554/22562087.e964>

Anesthetic considerations and postoperative pain management in radical penectomy: Case report

Penectomía radical, consideraciones anestésicas y manejo del dolor postoperatorio: Reporte de un caso

Juan Pablo Ghiringhelli M^{a,b}, Maryana López^c

^aAnesthesiology and Resuscitation Specialty, Medical School, Universidad de Valparaíso. Valparaíso, Chile.

^bAdmiral Nef Naval Hospital. Viña del Mar, Chile.

^cMedical School, Universidad de Talca. Talca, Chile.

Correspondence: Avenida Alessandri S/N, Hospital Naval Almirante Nef. Viña del Mar, Chile.

Email: juanpablo.ghiringhelli@uv.cl

How to cite this article: Ghiringhelli M. JP, López M. Anesthetic considerations and postoperative pain management in radical penectomy: Case report. Colombian Journal of Anesthesiology. 2021;49:e964.

Abstract

Radical penectomy (RP) is infrequently performed as it is reserved for specific cases of penile cancer, hence the paucity of reports regarding surgical and anesthetic considerations. Acute postoperative pain, chronic post-surgical pain, concomitant mood disorders as well as a profound impact on the patient's quality of life have been documented. This case is of a patient with diabetes and coronary heart disease, who presented with advanced, overinfected penile cancer, depressive disorder and a history of pain of neuropathic characteristics. The patient underwent radical penectomy using a combined spinal-epidural technique for anesthesia. Preoperatively, the patient was treated with pregabalin and magnesium sulphate, and later received a blood transfusion due to intraoperative blood loss. Adequate intra and postoperative analgesia was achieved with L-bupivacaine given through a peridural catheter during one week. Recovery was good, pain was stabilized to preoperative levels and the patient received pharmacological support and follow-up by psychiatry and the pain team.

Keywords

Radical penectomy; penile cancer; combined spinal-epidural anesthesia; acute postoperative pain; post surgical pain.

Resumen

La penectomía radical (PR) es una cirugía infrecuente, reservada para casos específicos de cáncer de pene, por lo que hay escasos informes sobre sus consideraciones quirúrgicas y anestésicas. Se ha documentado dolor agudo postoperatorio, dolor crónico posquirúrgico y alteraciones del estado de ánimo concomitantes, así como un profundo impacto en la calidad de vida posterior del paciente. Se presenta el caso de un paciente diabético y cardiópata coronario con cáncer de pene avanzado y sobreinfectado, trastorno depresivo y dolor previo de características neuropáticas, que recibe técnica combinada espinal-peridural para cirugía de penectomía radical. Se le trata también con pregabalina preoperatoria, sulfato de magnesio y transfusión por sangrado quirúrgico. Se otorgó una adecuada analgesia intra y postoperatoria, mediante catéter peridural con L-bupivacaína hasta por una semana. El paciente tuvo una buena recuperación, estabilización del dolor a niveles preoperatorios, controles y apoyo farmacológico por psiquiatría de enlace y equipo del dolor.

Palabras clave

Penectomía radical; cáncer de pene; anestesia peridural; dolor postoperatorio; dolor neuropático.

INTRODUCTION

Penile cancer is one of the less frequent urologic tumors, accounting for 2-3% of male urogenital tumors; in 95% of cases, it is a squamous cell carcinoma (1). Incidence tends to be higher in developing countries and it is associated with risk factors such as poor hygiene, smoking and infections such as human papilloma virus infection (2). It is usually a slowly growing tumor that spreads mainly through the lymphatics and requires surgery as standard treatment. Surgery consists of total tumor resection, attempting to preserve as much length as possible of healthy tissue that is functional for micturition and maintenance of sexual contact. Radical penectomy (RP) with perineal urethrostomy is performed in those cases in which the resection level is such that it preempts this goal (1).

Radical penectomy is infrequently performed and has precise indications which are increasingly the subject of controversy considering that meatal preservation is critical for quality of life (3). However, recent reports claim that RP is the main form of treatment in 15-20% of primary penile cancers (4).

There is scant information regarding anesthetic and perioperative considerations

related to this surgery, coming from isolated case presentations or in the form of extrapolations from penile prosthesis implant surgery. Some of the perioperative issues associated with RP include significant acute postoperative pain, bleeding, surgical wound infection and mood disorders (5-8).

We present the case of a patient with coronary heart disease and a psychiatric condition who presented with advanced, overinfected, penile cancer and underwent radical penectomy using a combined spinal-epidural (CSE) technique. The patient received intraoperative transfusion and was followed up by the pain team on a daily basis.

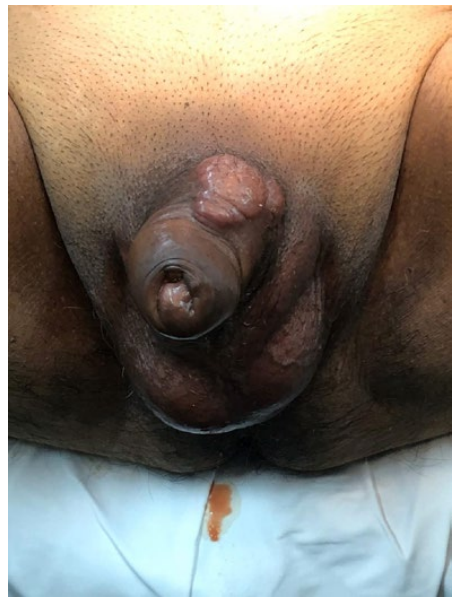CASE REPORT

A 65-year-old patient with a history of hypertension, non-insulin dependent diabetes mellitus type 2, dyslipidemia and percutaneous coronary revascularization with two stents performed 5 years before, on treatment with enalapril, metformin, bisoprolol, rosuvastatin and aspirin. Surgical history included appendectomy and vasectomy, with no reported incidents during anesthesia. The patient was functional class I and a preoperative

echocardiography performed 4 months before showed good global and segmental systolic function. The patient signed the informed consents for surgery and anesthesia and gave his permission for photographic documentation. Approval was obtained from the Scientific Ethics Committee of Admiral Nef Naval Hospital (July 2017).

The patient presented in July 2017 with a penile tumor. The incisional biopsy performed under local anesthesia showed a well differentiated, eroded and infiltrating squamous cell carcinoma. However, the patient refused surgery and chose alternative medicine therapies. In August 2019, the patient presented with stabbing and burning genital pain, grade 4 on the Visual Analog Scale (VAS), and findings of purulent secretion and enlarged glans (Figure 1), fever and altered general status. Significant results of the laboratory tests performed on admission included Hb of 7.2; creatinine 1.73; increased inflammatory parameters (C-reactive protein and leukocyte count), hyperglycemia, and inflammatory urine sediment with abundant bacteria. The approach to management was antibiotic therapy, hematocrit optimization with red blood cell transfusion and compensation of pre-renal

FIGURE 1. Painful preoperative lesion at the base of the penis.



SOURCE: Authors.

TABLE 1. DN4 Questionnaire.

Parameter	Description	Score
Question 1: Does your pain have one or more of the following characteristics?	1. Burning	1
	2. Painful cold	1
	3. Electric shocks	1
Question 2: Is the pain associated with one or more of the following symptoms in the same area ?	4. Tingling	1
	5. Pins and needles	1
	6. Numbness	1
	7. Itching	1
Question 3: Is the pain located in an area where the physical examination had one or more of the following characteristics?	8. Hypoesthesia to touch	1
	9. Hypoesthesia to pricks	1
Question 4: In the painful area, can the pain be caused or increased by:	10. Brushing	1
		Patient score: ____/10

Every positive response is assigned 1 point and every negative response is 0. Points are added and if the total score is equal to, or greater than 4, pain is classified as neuropathic.

SOURCE: . Adapted by the authors from Bouhassira (9).

failure and diabetes. The patient was also found to be anhedonic and emotionally labile and was diagnosed with major depressive disorder which was treated with citalopram. One week after admission, the patient was scheduled for surgical resection of a stage IIIB penile cancer, T₃N₂M₀, in two stages: 1) radical penectomy and 2) bilateral inguinal lymphadenectomy (with a 1-month interval), due to the existing infectious compromise.

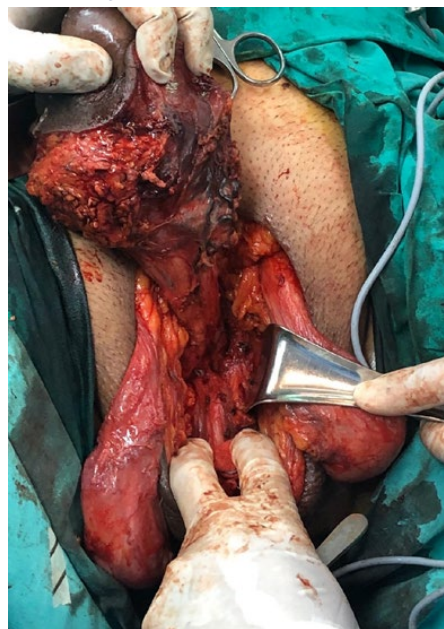The preoperative physical examination showed preputial edema preventing glans coverage, together with a hard mass adjacent to the base of the penis (Figure 1). Additional workup included a bone scan which showed no evidence of secondary bone involvement, and computed axial tomography (CT scan) of the chest, abdomen and pelvis that revealed the penile mass already described plus bilateral inguinal lymphadenopathy. Pain was classified by the pain team as somatic and neuropathic based on a pain score of 4 using the DN4 questionnaire (Table 1) for burning genital pain. Pregabalin at a dose of 75 mg/day was initiated five days before the surgery.

Every positive response is assigned 1 point and every negative response is 0. Points are added and if the total score is equal to, or greater than 4, pain is classified as neuropathic.

On arrival of the patient at the ward, monitoring was established with electrocardiography (EKG), heart rate (HR), non-invasive blood pressure (NIBP) and pulse oximetry (SatO₂). Two peripheral venous accesses (# 16 and # 18) were established uneventfully. With the patient in the sitting position, a combined spinal-epidural anesthesia technique was used at the L₃-L₄ space using a #16 peridural catheter and a long #27 catheter for the spinal component after infiltrating with 2% lidocaine, with injection of 12.75 mg of hyperbaric bupivacaine and 15 µg of fentanyl. The peridural catheter was then fixed at 12 cm. The setup time was 16 minutes. The patient refused sedation.

With the patient placed in modified lithotomy position, radical penectomy

FIGURE 2. Radical penectomy, with sectioning of the corpora cavernosa.

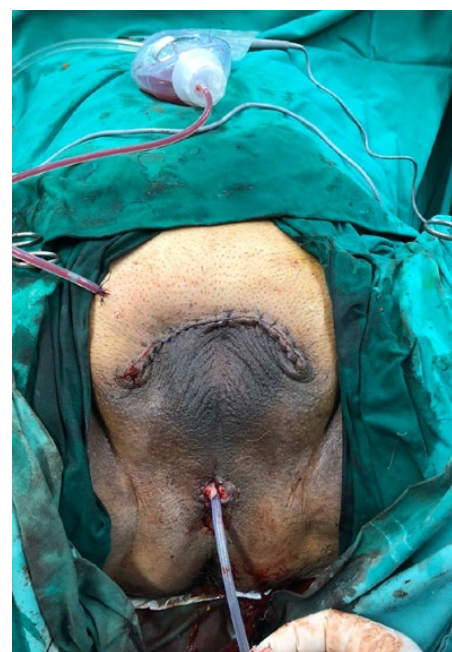

SOURCE: Authors.

(sectioning both corpora cavernosa) was then performed, leaving a perineal urethrostomy (Figures 2, 3 and 4).

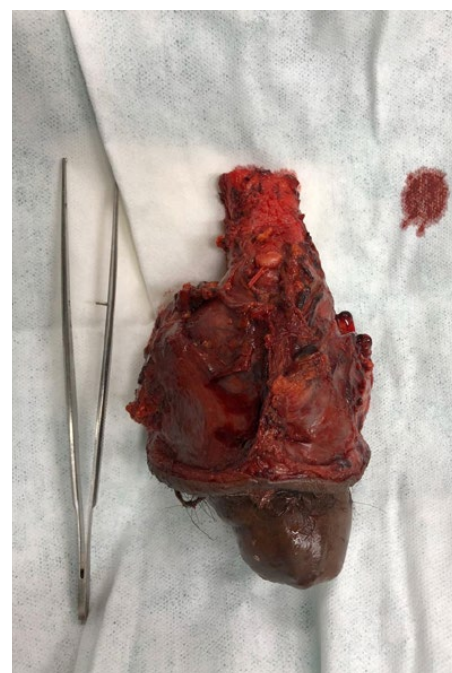The patient received tranexamic acid, ephedrine 6 mg, magnesium sulphate 1.25 g and paracetamol 1 g, plus antibiotic therapy according to schedule. Two units of red blood cells were transfused due to blood loss of approximately 700 cm³. Surgical time was 115 minutes. The patient was transferred to the step-down unit for postoperative recovery, with the following vital signs on arrival: BP 114/74, HR 67 and 98% ambient Sato₂, no fever and a score of 0 on the Visual Analogue Scale (VAS). The patient had a stable course over the next few days, with static and dynamic VAS pain scores of 1 and 2 (average during the first 96 hours), respectively, treated with peridural patient controlled analgesia (PCA) consisting of 0.125% levobupivacaine initially set at 5 (mL/h infusion), 5 (mL bolus as required by the patient) and 20 (20 minute block). Additionally, paracetamol, pregabalin and citalopram were also used. The VAS and peridural infusion data are shown in Figure 5. Because of high daily requirements (average demand of 35

FIGURE 3. Surgical wound after radical penectomy with perineal urethrostomy and Jackson Pratt surgical drain.



SOURCE: Authors.

FIGURE 4. Surgical specimen of penile cancer arising from the balanopreputial sulcus and infiltrating the fascia, tunica albuginea and tunica dartos, corpora cavernosa and periurethral spongy tissue.



SOURCE: Authors.

boluses per day, with 25 administered), the peridural catheter was left in place for seven days, with a good response as shown by a daily VAS score < 2. After peridural PCA removal, pain increased to 4 on the VAS, requiring the administration of intravenous analgesia and an increased dose of pregabalin. Because of the development of surgical wound infection, the patient received 10 days of antibiotic treatment with amikacin and was seen on a daily basis by the psychologist due to exacerbation of his psychiatric condition. The patient was discharged on postoperative day 16 with a score of 1 on the VAS and a score of 2 on the DN4.

After a one-month interval, the patient was brought back for bilateral lymphadenectomy, again using the CSE technique, with good postoperative course, removal of the peridural PCA on the second postoperative day and discharge after 7 days. The patient was later started on radiotherapy.

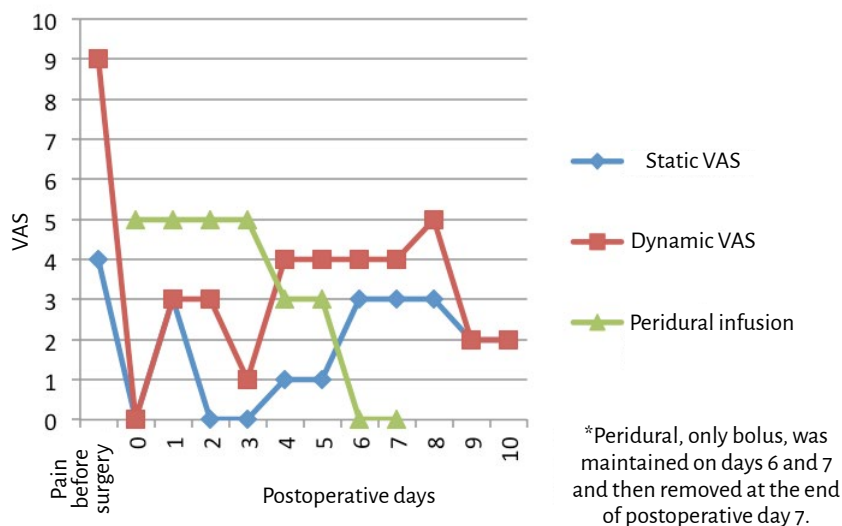
Monthly follow-up was indicated with the participation of a multidisciplinary team consisting of psychiatry, urology, and pain clinic. Treatment was maintained with citalopram 20 mg every 12 hours, pregabalin 150 mg every 12 hours and paracetamol 1 g every 8 hours, with good postoperative course, improved mood and sleep, and a VAS of 2.

Twelve months later, the patient presented with fever and hypotension associated with a painful mass in the right thigh; a CT scan of abdomen and pelvis revealed a relapsing pelvic mass, bladder metastasis and iliac and periaortic lymphadenopathy. The patient and the family declined any future interventions and decided on referral to palliative care. Pregabalin was maintained and the patient was started on the use of buprenorphine patches. The patient died two months later at home.

DISCUSSION

Radical penectomy has a profound impact on the patient's psychological condition, sexual life and quality of life, as illustrated by this case of a patient who suffered from anxiety disorders and depressive syndrome

FIGURE 5. Pain assessment 10 days after RP and peridural infusion.



VAS: Visual Analog Scale. **SOURCE:** Authors.

TABLE 2. Perioperative considerations in radical penectomy with corresponding strategies.

Considerations	Strategy
Acute severe postoperative pain	Multimodal analgesia, prefer regional or combined techniques
Surgical nerve injury, risk of chronic post-surgical neuropathic pain	Daily follow-up by pain unit and avoid early removal of peridural catheters. Multimodal analgesia/regional technique
Profuse bleeding	Large venous accesses, reserve of blood products, individualized transfusion. Tranexamic acid.
High incidence of surgical wound infection	Broad spectrum antibiotic therapy. Multimodal analgesia.
Concomitant psychosomatic disorders	Psychiatric assessments, family support and pharmacological treatment. Multimodal analgesia.
Perineal urethrostomy stenosis	Regular nursing and urology follow-up.

SOURCE: Adapted by the authors from Savu et al., (5); Yadav et al., (6); Reinstatler et al., (7) y Croll et al. (8).

(10). Table 2 summarizes the perioperative considerations with their respective strategies derived from different clinical cases used in this report.

The penis has a rich blood and nerve supply. Nerves frequently involved in penile pain are afferent nerve endings in the skin, glans, urethra and corpora cavernosa. The main nerve blocks for penile surgery

focus on the dorsal nerve of the penis, the pudendal nerve and the sacral roots (7). The use of low lumbar CSE helps block those roots and treat pain at the point of origin. Moreover, patients who received regional anesthesia for penile surgery described less postoperative pain and required less opioid use when compared to patients who received general anesthesia (11).

Acute postoperative pain is the most frequent preoperative concern for the patients (12), because, if not treated adequately, it may become chronic. Post-surgical neuropathic pain is a highly underestimated clinical problem. It is estimated that it can be as high as 10% in oncologic surgery, urologic surgery accounting for many of those cases (13). Probably due to perineural permeation and infectious involvement, this patient reported preoperative pain, with the subsequent risk of chronic post-surgical pain, which is consistent with urologic surgery studies that report prior pain in 20% of patients (14). Other risk factors for chronic post-surgical pain are pre-existing emotional distress, prior opioid use, previous surgery in the same site, and acute postoperative pain (15). Two of these factors (pre-existing pain and emotional distress) were present in this patient. Moreover, RP requires nerve sectioning, another factor that has been implicated in the development of chronic pain (15). Therefore, the anesthetist plays a critical role in pain prevention and management following RP, given that prophylactic strategies are more cost-effective than allowing the pain to become persistent. In this case, the technique used were:

- **Peridural analgesia.** By minimizing signal transmission to the spinal cord, nociceptive transmission to the dorsal horn can be prevented, avoiding central sensitization (15). Regional techniques have been shown to reduce the risk of chronic post-surgical pain in thoracotomy and breast surgery (16). Also, spinal anesthesia has been found to reduce the incidence of post-procedural chronic pain in cesarean section, when compared to general anesthesia (17). Although evidence is lacking in RP, the mechanism of chronic pain reduction could be assumed to be similar. In this patient, the use of a peridural catheter contributed to a faster recovery, better control of the psychiatric disorders and higher satisfaction. It also helped diminish surgical wound infection through modulation of the inflammatory response to the surgery and improved tissue oxygenation (18).
- **Pregabalin** is a gabapentinoid that acts on

presynaptic calcium channels. Good quality studies have shown that its preventive use may reduce chronic post-surgical pain (15).

- **As part of multimodal analgesia,** magnesium sulphate and paracetamol contribute to a shorter length of stay and opioid sparing, with the resulting reduction of opioid-related adverse effects (19). Magnesium sulphate is an N-methyl-D-aspartate (NMDA) glutamatergic receptor antagonist, therefore playing a key role in the management of postoperative pain and hyperalgesia as it reduces hyperexcitability and sensitization (15). Moreover, this patient was not a candidate for non-steroidal anti-inflammatory drugs because of the history of renal failure.

- **Psychosocial factors.** Pharmacological treatment and psychotherapy to optimize sleep and mood before the surgery contributed to a good recovery in this patient.

Following major urologic surgery, pain on the second postoperative day is described with a score of 4 on a scale of 0 to 10 which gradually drops to 1 after 6 months, with close to 2% of patients using oral opioids (15). Although there is a paucity of reports on VAS scores after RP, the assumption is that the situation could at least be similar.

As far a survival after RP is concerned, because it is mostly performed in patients with advanced-stage disease, more than 40% will die within the first 5 years, while 60% will relapse (4,20). This patient was no exception because he died one year after the surgery. However, despite this unfavorable outcome, individual case reports like the one described in this paper shed light on perioperative considerations and intra and postoperative pain management that can serve as a basis for the development of recommendations based on further larger scale studies.

ETHICAL RESPONSIBILITIES

Approval by the Ethics Committee

The Scientific Ethics Committee of Admiral Nef Naval Hospital granted approval in July 2017.

Human and animal protection

The authors declare that no human or animal experiments were conducted as part of this research.

Data confidentiality

The authors declared that they followed the protocols of their institution regarding patient data disclosure, ensuring confidentiality in accordance with the principles of the Declaration of Helsinki.

Right to privacy and informed consent

The authors obtained the informed consent of the patients and/or subjects referred to in this paper. The document is kept by the corresponding author.

ACKNOWLEDGEMENTS

Authors' contributions

JG, ML: Conducted the research and wrote the manuscript.

Assistance for the study

None declared.

Financial support

No sponsorship was received by the authors for this work.

Conflict of interest

The authors declare having no conflict of interest.

Presentations

None declared.

Appreciation

The authors are grateful to the patient and his family, in particular his daughter. To the anesthesia, psychiatry and urology team of Admiral Nef Naval Hospital.

REFERENCES

1. Neveu CR, Bórquez MP, Trujillo LC, Fernández R, Buchholtz FM. Experiencia de 10 años en el manejo del cáncer de pene, Instituto Nacional del Cáncer (1997-2006). *Rev Chil Cir [Internet]*. 2008;60(2):103-7. doi: <http://dx.doi.org/10.4067/S0718-40262008000200004>.
2. Moses KA, Winer A, Sfakianos JP, Poon SA, Kent M, Bernstein M, et al. Contemporary management of penile cancer: greater than 15 year MSKCC experience. *Can J Urol*. 2014;21(2):7201-6.
3. Sosnowski R, Kulpa, M, Kosowicz M, Wolski J, Kuczkiewicz O, Moskal K, et al. Quality of life in penile carcinoma patients-post-total penectomy. *Cen European J Urol*. 2016;69(2):204-11. doi: <https://doi.org/10.5173/cej.u.2016.828>
4. Ghahhari J, Marchioni M, Spiess PE, Chipollini JJ, Nyirády P, Varga J, et al. Radical penectomy, a compromise for life: results from the PECAD study. *Transl Androl Urol*. 2020;9(3):1306-13. doi: <https://doi.org/10.21037/tau.2020.04.04>
5. Savu C, Surcel C, Mirvald C, Gîngu C, Hortopan M, Sinescu I. Atypical primary tuberculosis mimicking an advanced penile cancer. Can we rely on preoperative assessment? *Rom J Morphol Embryol*. 2012;53(4):1103-6. [citado 2020 ago 22]. Disponible en: <https://rjme.ro/RJME/resources/files/53041211031106.pdf>
6. Yadav K, Minhas R. Radical penectomy: procedure details of an uncommonly performed procedure for carcinoma penis and review of literature. *Cancer Rep Rev*. 2018;2. doi: <https://doi.org/10.15761/CRR.1000149>
7. Reinstatler L, Shee K, Gross MS. Pain management in penile prosthetic surgery: A review of the literature. *Sex Med Rev*. 2018;6(1):162-9. doi: <https://doi.org/10.1016/j.sxmr.2017.05.005>
8. Croll B, Voznesensky M. A case of phantom penile pain following penectomy. *J Uro Neph Re Cas Rep*. 2018;101. [citado 2020 ago 22]. Disponible en: <http://www.scientizepublishers.com/wp-content/uploads/2020/03/2018-JUNRCR-101.pdf>
9. Bouhassira D, Attal N, Alchaar H, Boureau F, Brochet B, Bruxelle J, et al. Comparison of pain syndromes associated with nervous or somatic lesions and development of a new Neuropathic pain diagnostic questionnaire (DN4). *Pain*. 2005;114:29-36. doi: <https://doi.org/10.1016/j.pain.2004.12.010>
10. Maddineni SB, Lau MM, Sangar VK. Identifying the needs of penile cancer sufferers: a systematic review of the quality of life, psychosexual and psychosocial literature in penile cancer. *BMC Urol*. 2009;9:8. doi: <https://doi.org/10.1186/1471-2490-9-8>
11. Henry GD, Saccà A, Eisenhart E, Cleves MA, Kramer AC. Subarachnoid versus General Anesthesia in Penile Prosthetic Implantation: Outcomes Analyses. *Adv Urol*. 2012;2012:696752. doi: <https://doi.org/10.1155/2012/696752>
12. Shipton E. Post-surgical neuropathic pain. *ANZ J Surg*. 2008;78(7):548-5. doi: <https://doi.org/10.1111/j.1445-2197.2008.04569.x>
13. Jain P, Padole D, Bakshi S. Prevalence of acute neuropathic pain after cancer surgery: A prospective study. *Indian J Anaesth*. 2014;58(1):36-42. doi: <https://doi.org/10.4103/0019-5049.126788>
14. Laufenberg-Feldmann R, Kappis B, Mauff S, Schmidtman I, Ferner M. Prevalence of pain 6 months after surgery: a prospective observational study. *BMC Anesthesiol*. 2016;16(1):91. doi: <https://doi.org/10.1186/s12871-016-0261-7>
15. Reddi D, Curran, N. Chronic pain after surgery: pathophysiology, risk factors and prevention. *Postgrad Med J*. 2014;90(1062):222-6. doi: <https://doi.org/10.1136/postgradmedj-2013-132215>
16. Andrae MH, Andrae DA. Regional anaesthesia to prevent chronic pain after surgery: a Cochrane systematic review and meta-analysis. *Br J Anaesth*. 2013;111(5):711-20. doi: <https://doi.org/10.1093/bja/aet213>
17. Nikolajsen L, Sørensen HC, Jensen TS, Kehlet H. Chronic pain following Caesarean section. *Acta Anaesthesiol Scand*. 2004;48(1):111-6. doi: <https://doi.org/10.1111/j.1399-6576.2004.00271.x>
18. Sessler DI, Neuraxial Anesthesia and Surgical Site Infection. *Anesthesiology*. 2010;113(2):265-7. doi: <https://doi.org/10.1097/ALN.0b013e3181e2c1ed>.
19. Urman RD, Boing EA, Pham AT, et al. Improved outcomes associated with the use of intravenous acetaminophen for management of acute post-surgical pain in cesarean sections and hysterectomies. *J Clin Med Res*. 2018;10(6):499-507. doi:10.14740/jocmr338ow doi: <https://doi.org/10.14740/jocmr338ow>
20. Montiel-Jarquín Á, Contreras-Díaz AJ, Vázquez-Cruz E, Chopin-Gazga MA, Romero-Figueroa MS, Etchegaray-Morales I, et al. Análisis de supervivencia a cinco años en pacientes con cáncer de pene [Five-year survival analysis in patients with penile cancer]. *Rev Med Inst Mex Seguro Soc*. 2017;55(Suppl 1):S34-S43. Disponible en <https://www.medigraphic.com/pdfs/imss/im-2017/ims171f.pdf>